

# Mesa Redonda Manejo del Cancer de Tiroides

Ricard Simo FRCS (ORL-HNS) PhD



SOCIETAT CATALANA  
D'OTORINOLARINGOLOGIA  
I PATOLOGIA CERVICO-FACIAL



# Panelistas



Profesor Javier Gavilan  
Hospital de la Paz  
Universida Autonoma de Madrid



Dr Ricard Mesia  
Institut Catala  
d'Oncologia  
Badalona



Dr Joan Verges  
Hospital Germans Tries  
Barcelona



Dr Jaume Puig de Dou  
Endocrino  
Hospital del Mar  
Barcelona

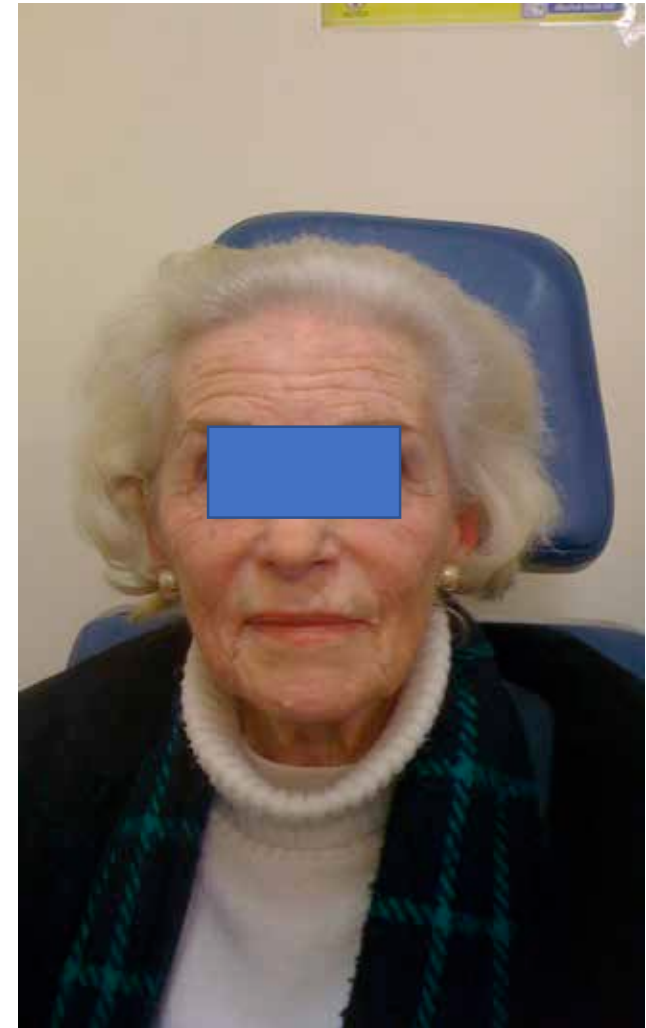# Objetivos

- Comité de Tumores de cáncer de tiroides
- Discutir diferentes escenarios de cáncer de tiroides
- Resaltar controversias en el manejo del cáncer de tiroides
- Discutir aspectos referentes a la evaluación, manejo quirúrgico, manejo no quirúrgico, estratificación del riesgo, seguimiento y terapias adyuvantes
- Estimular a la audiencia para la participación

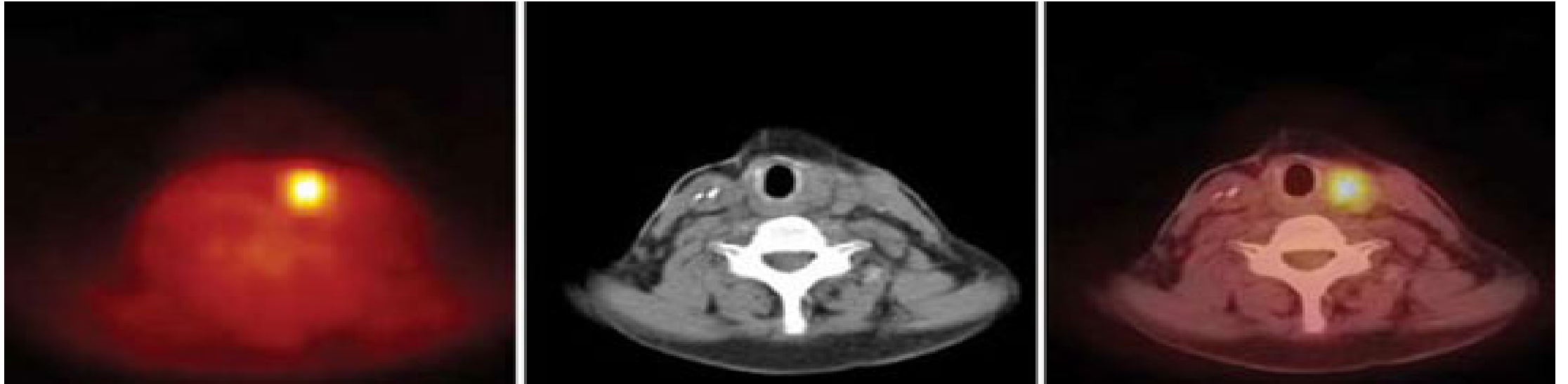
# Thyroid Clinical Case 1

# Clinical Summary

- 79 years old referred by HM at GSTT
- PC: Malignant Melanoma right foot treated with WSE
- and right inguinal dissection
- June 2010 – PET CT Uptake Left thyroid lobe - **SUV 9**
- Thyroid status: Euthyroid
- FNAC: Thy 3a Bethesda III
- PMH: Osteoporosis and OA
- FH: None significant
- ECoG PS: 2
- Smokes: None smoker
- Alcohol: Socially
- SH: JW, retired WHO PA and lives alone

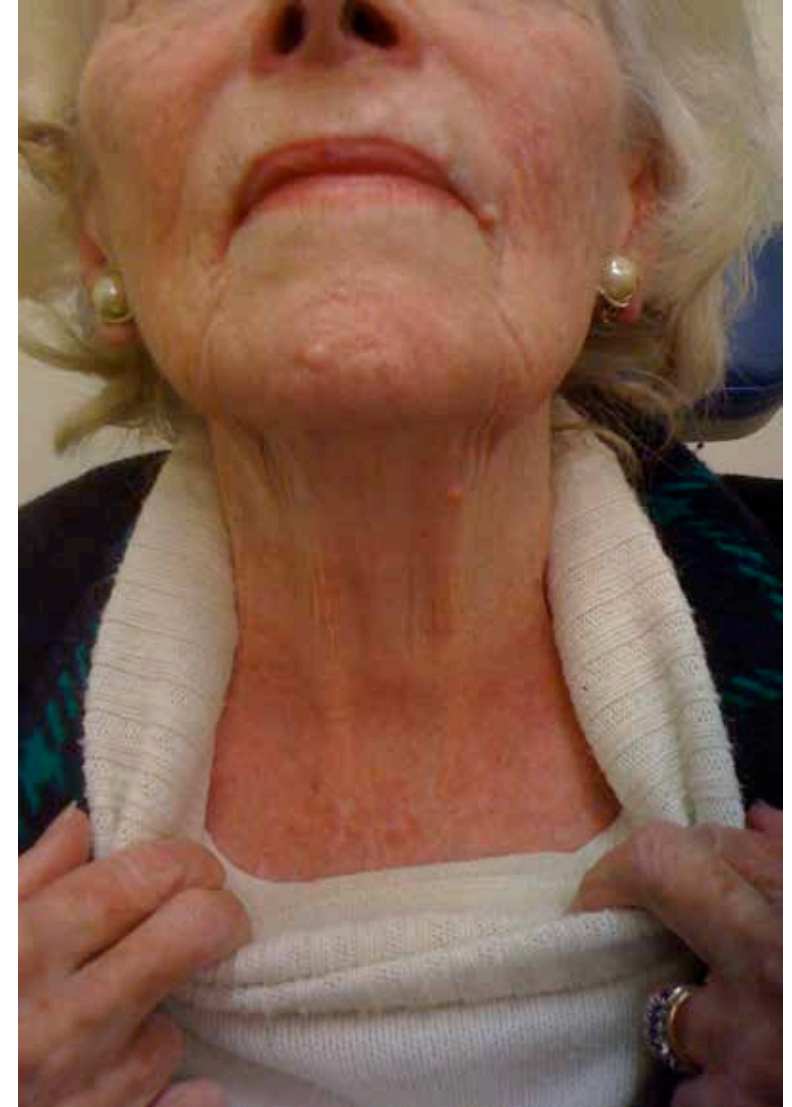


# PET-CT



# Clinical Findings

- 2x2 cm left STN irregular and hard
- C and r N0
- cMx
- U5 on USS



# Proposed Treatment

- Diagnostic?
- left thyroid lobectomy and level VI exploration



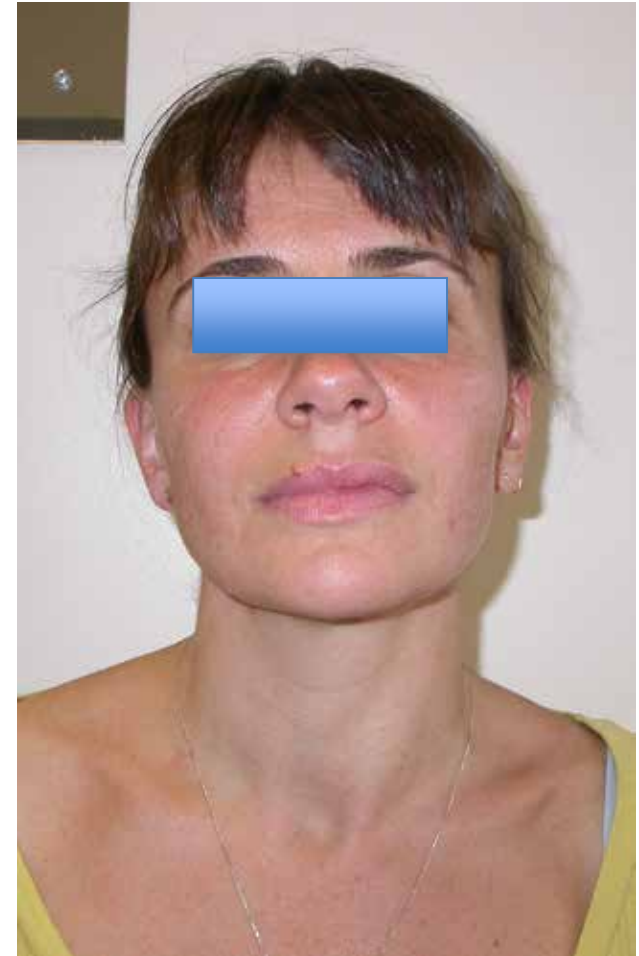# Histopathological Findings and Further Treatment

- pT2 -2.5 x 2.5 encapsulated PTCa – No aggressive features
- N0 0/4 Lymph nodes
- ? Any further treatment

# Thyroid Clinical Case 2

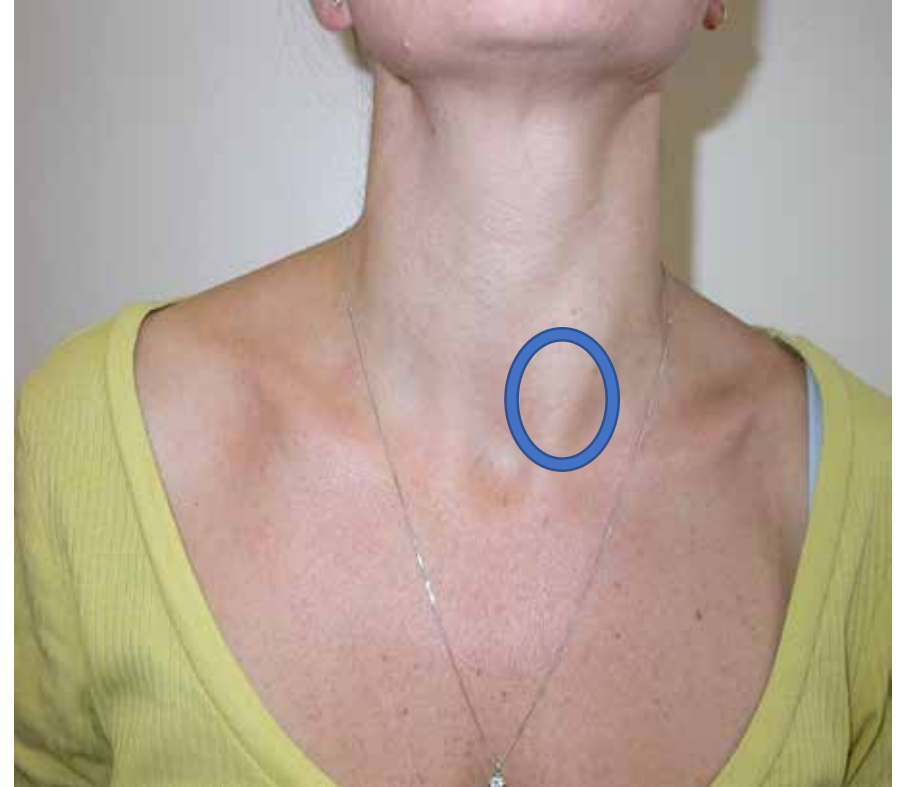# Clinical Summary

- 39 years old referred by Endocrinology
- PC: Left STN increasing in size since 2001
- Thyroid status: Euthyroid
- FNAC: Initially Thy 3 f Bethesda 4 and review by central MDM Thy 3f
- PMH: Anaemia
- FH: Mother and sister with hypothyroidism
- ECoG PS: 0
- Smokes: Non-smoker
- Alcohol: 14 units / week
- SH: TV producer, lives with husband and 2 children

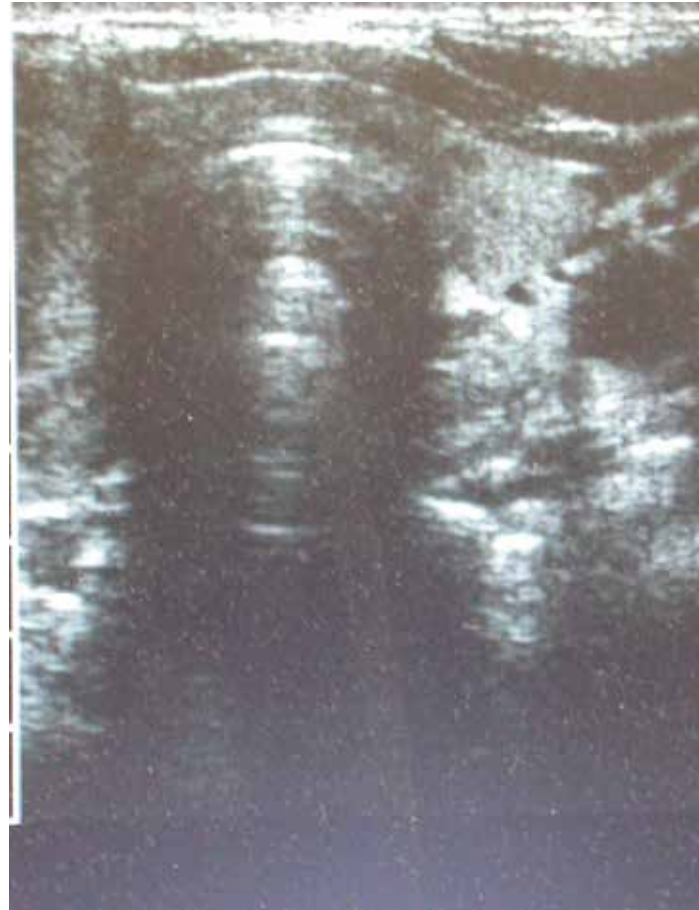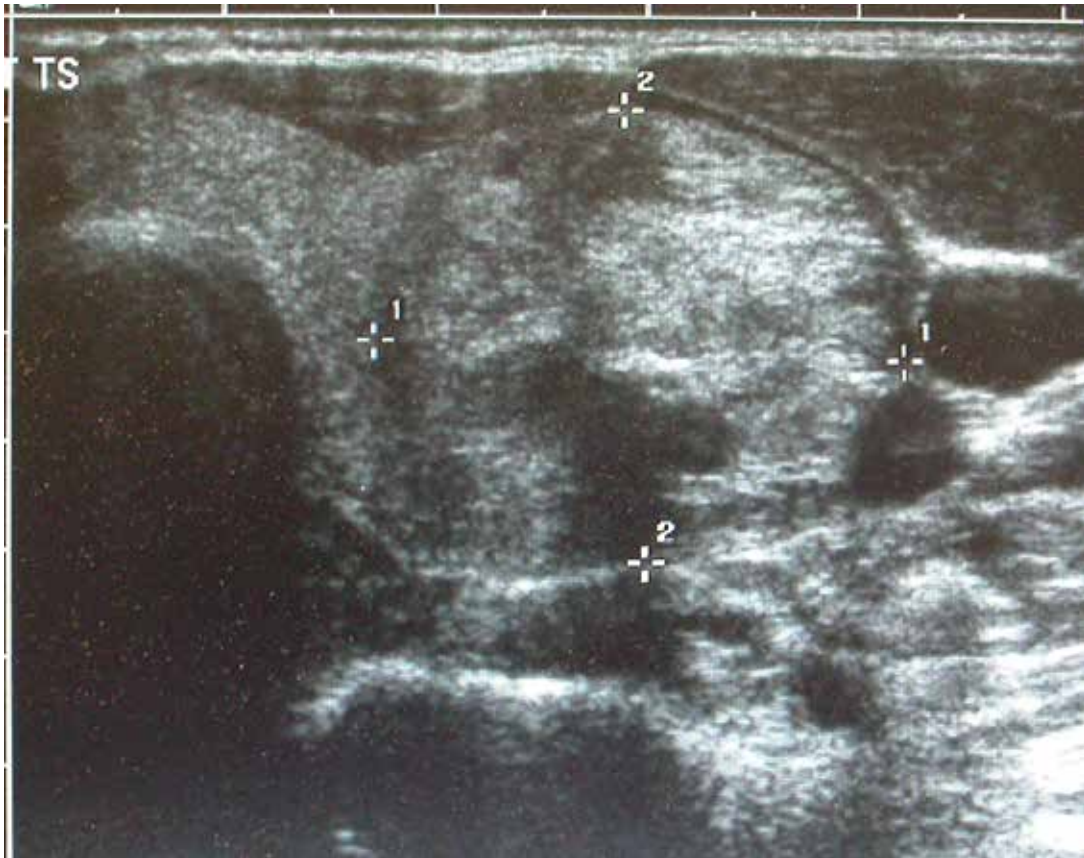


# Clinical Findings

- cT2 3x2 cm left thyroid nodule with irregular capsule
- cN0
- cMx



# USS Findings



# Proposed Treatment

- **Diagnostic L Thyroid Lobectomy!!!!!!**

# Histopathology

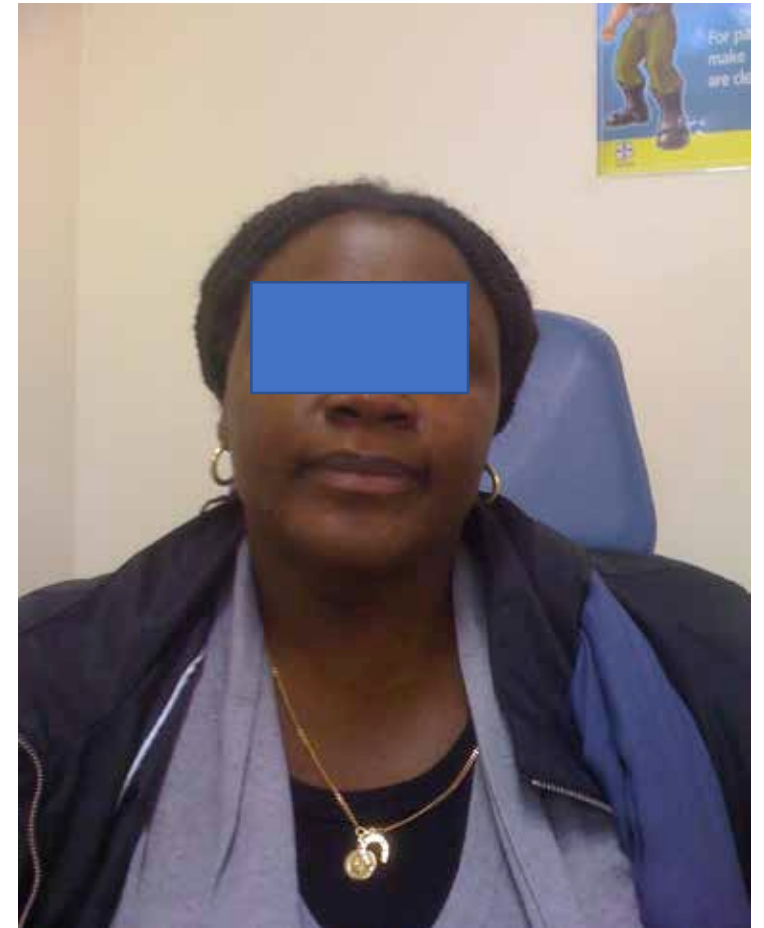- 2cm papillary thyroid carcinoma with 3 mm satellite micropapillary
- Pre-cricoid lymph node – metastatic micropapillary carcinoma
  
- What next?

# Clinical Case 3



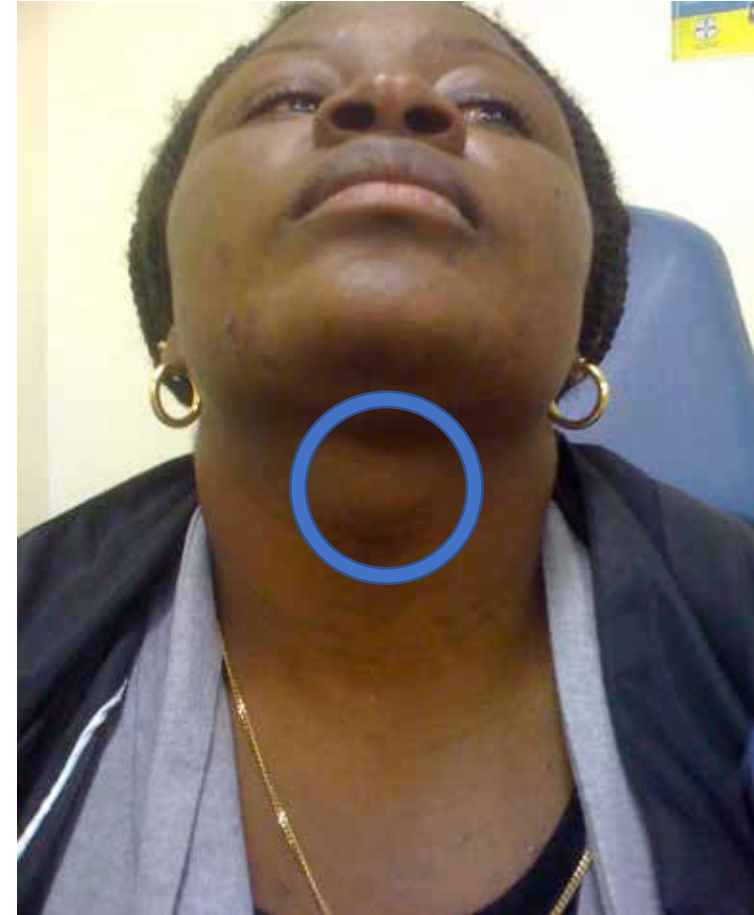# Clinical Summary

- 31 years old house wife referred by AFO at GSTT
- PC: 10 years history of midline neck mass at the level of hyoid bone clinically compatible with a thyroglossal duct cyst
- Thyroid status: Euthyroid
- FNAC: Thy 3f Bethesda 4
- USS and MRI scan: Microcalcification and 2 nodules right thyroid lobe
- PMH: Allergic rhinitis and depression
- FH: None significant
- ECoG PS: 0
- Smokes: Non-smoker
- Alcohol: Rare
- SH: Lives alone with 4 children

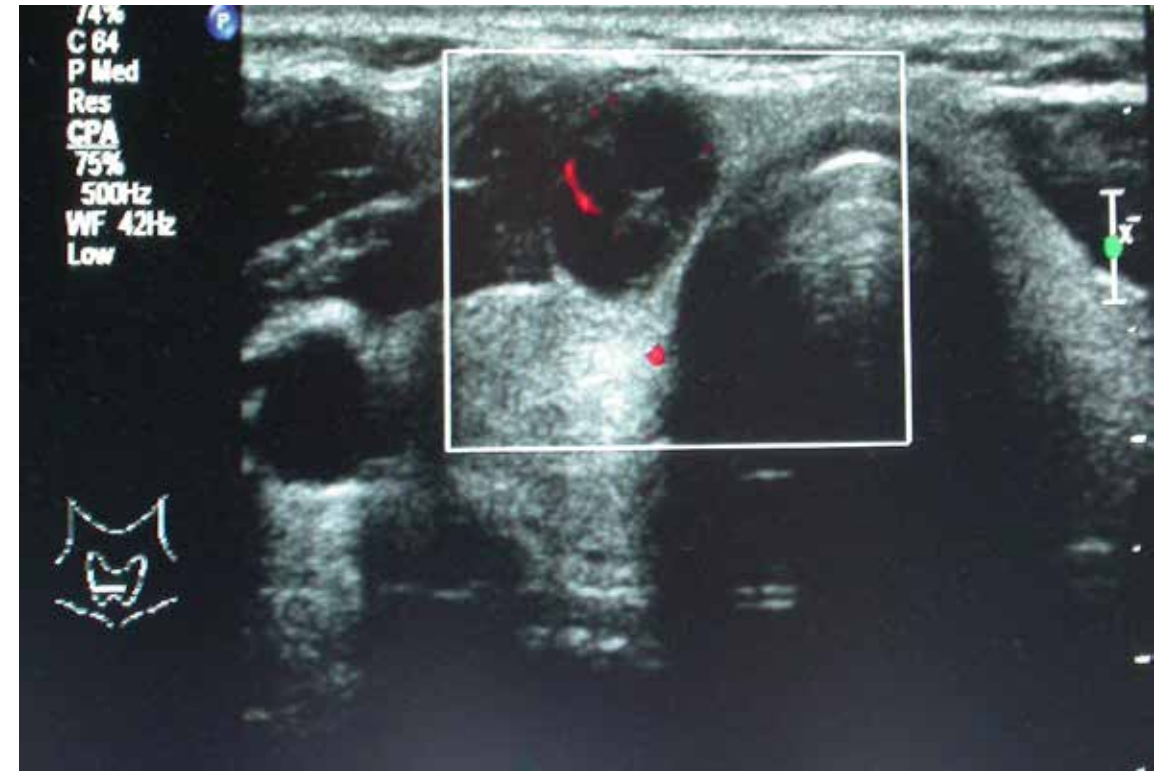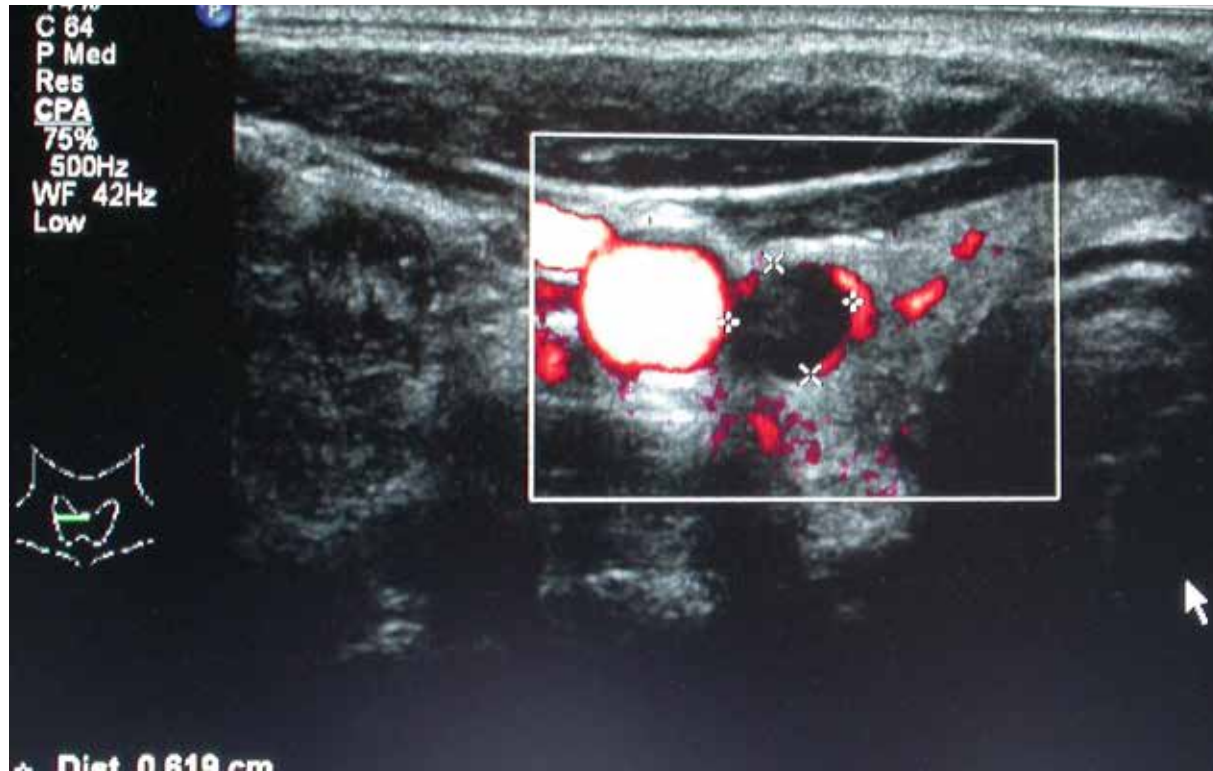


# Clinical Findings

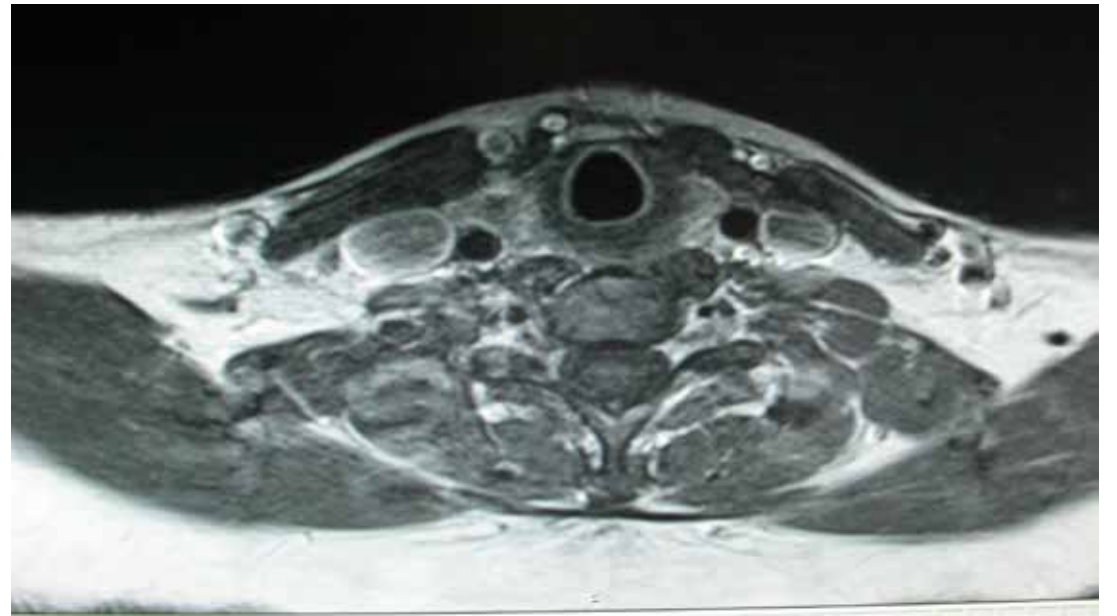
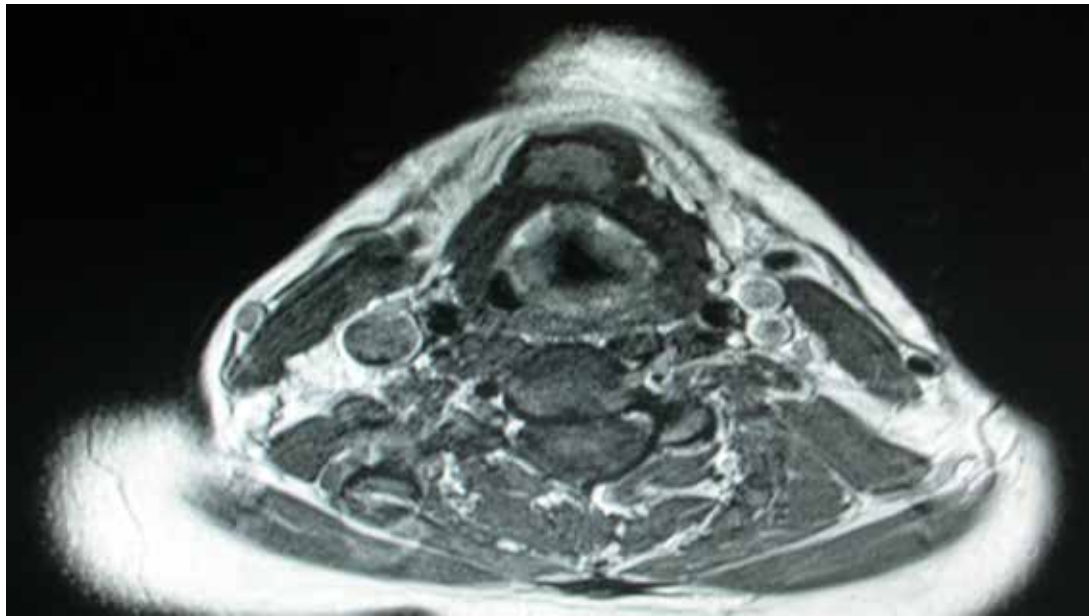
- cT2 3x3 cm thyroglossal duct solid mass
- cN0
- cMx



# USS Findings



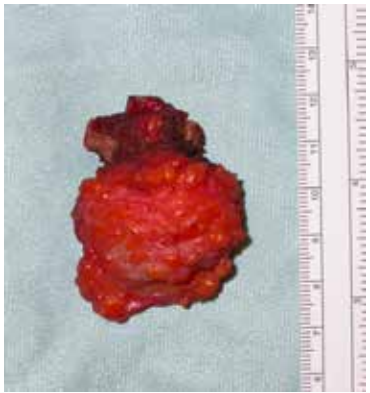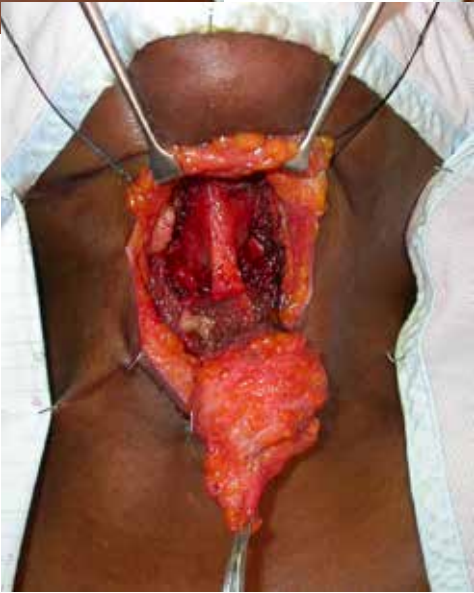
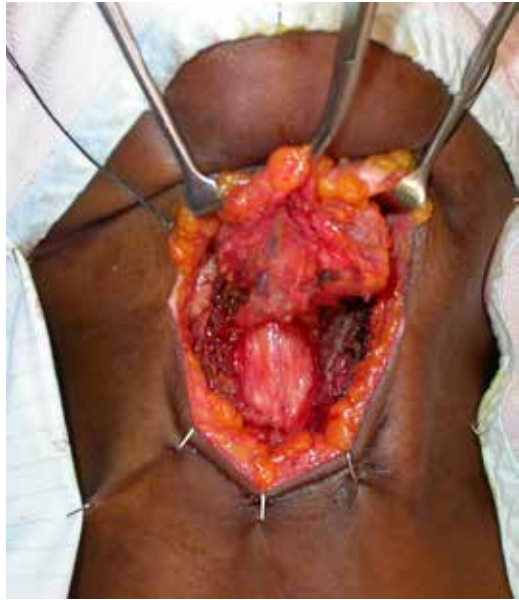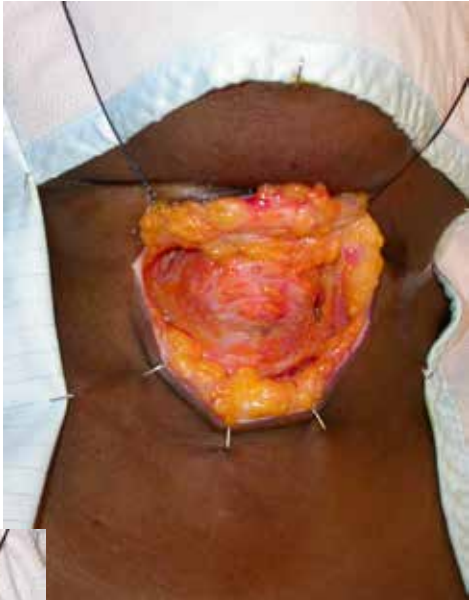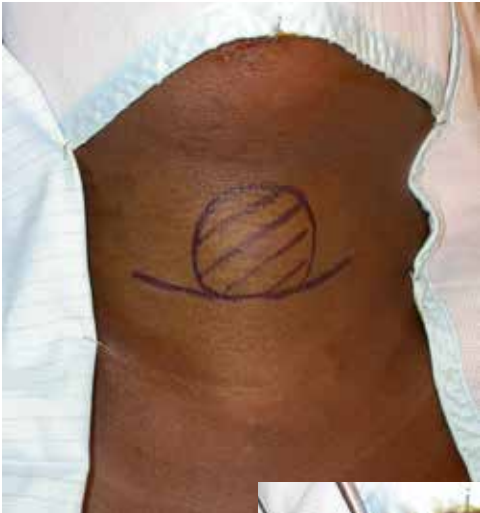# MRI Scan Findings



# Proposed Treatment

- Patient not keen on surgery and she thinks that she is pregnant
- What next?
- What metabolic changes pregnancy may have on the thyroid?

# Surgery



# Histopathology

- 4 x 4 cm thyroglossal duct cyst completely replaced by PTC and abutting the capsule
- What next?

# Clinical Case 4

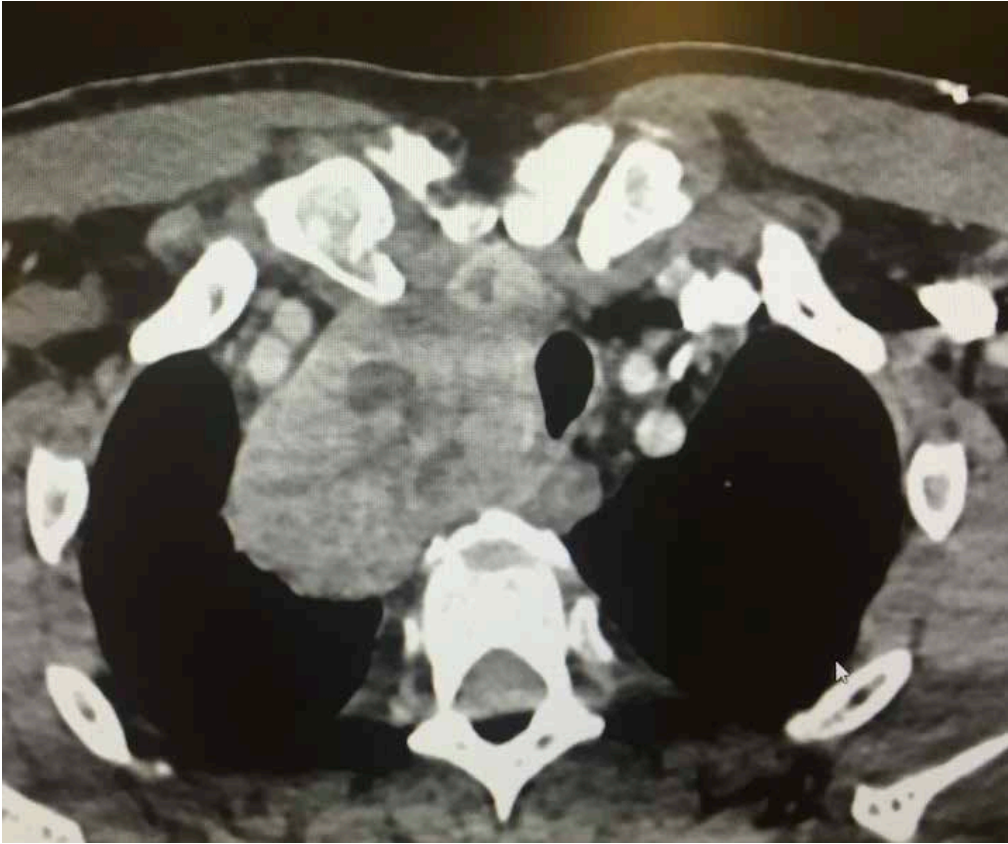
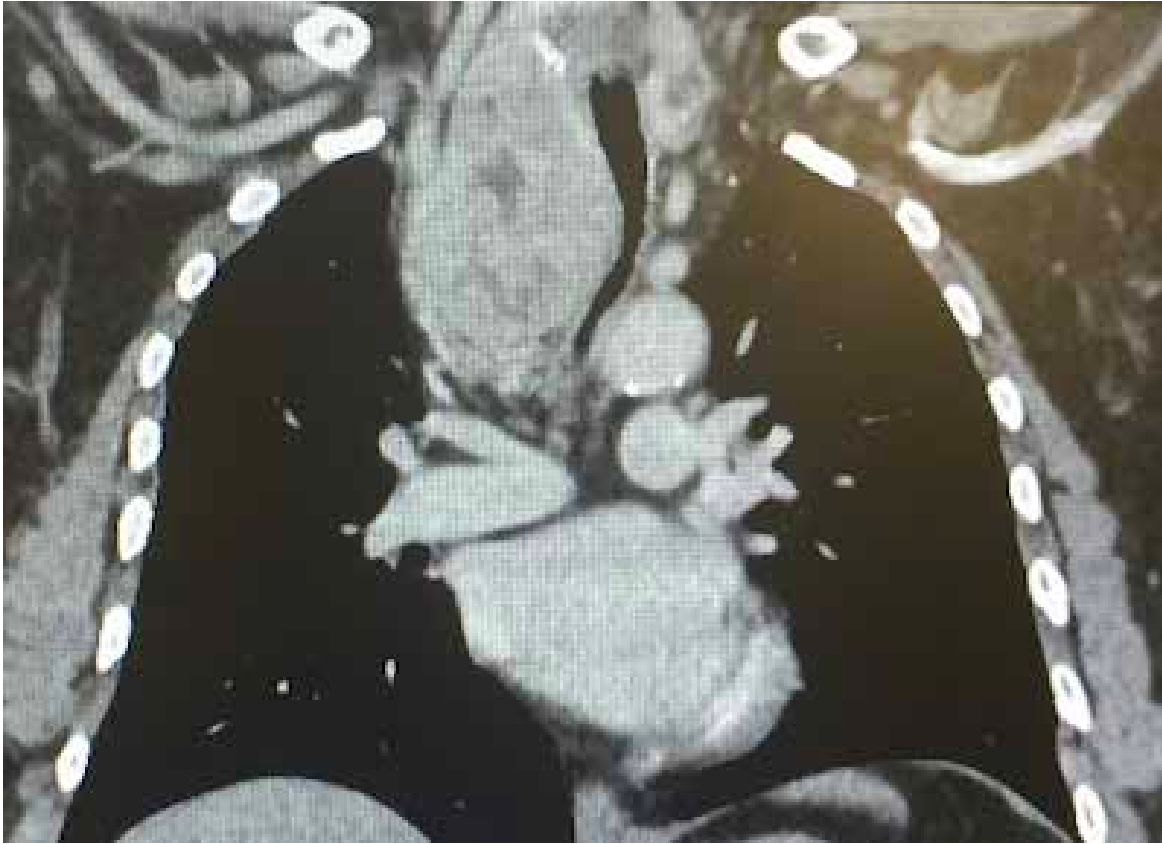
# Clinical Summary 4

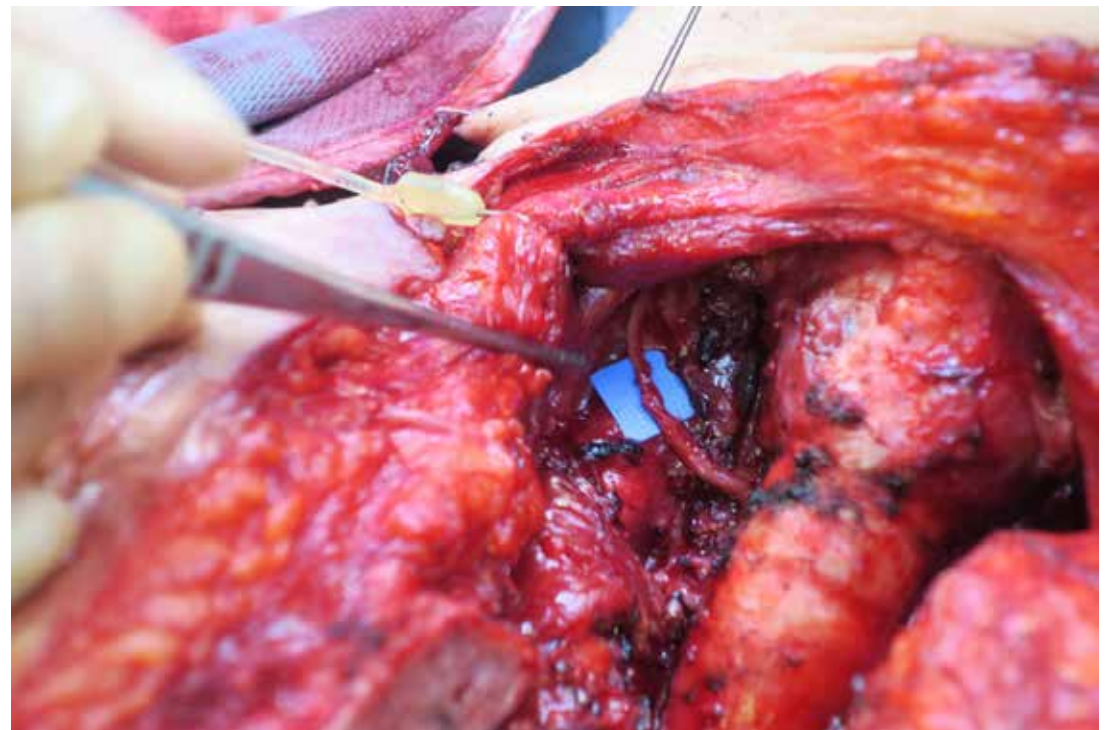
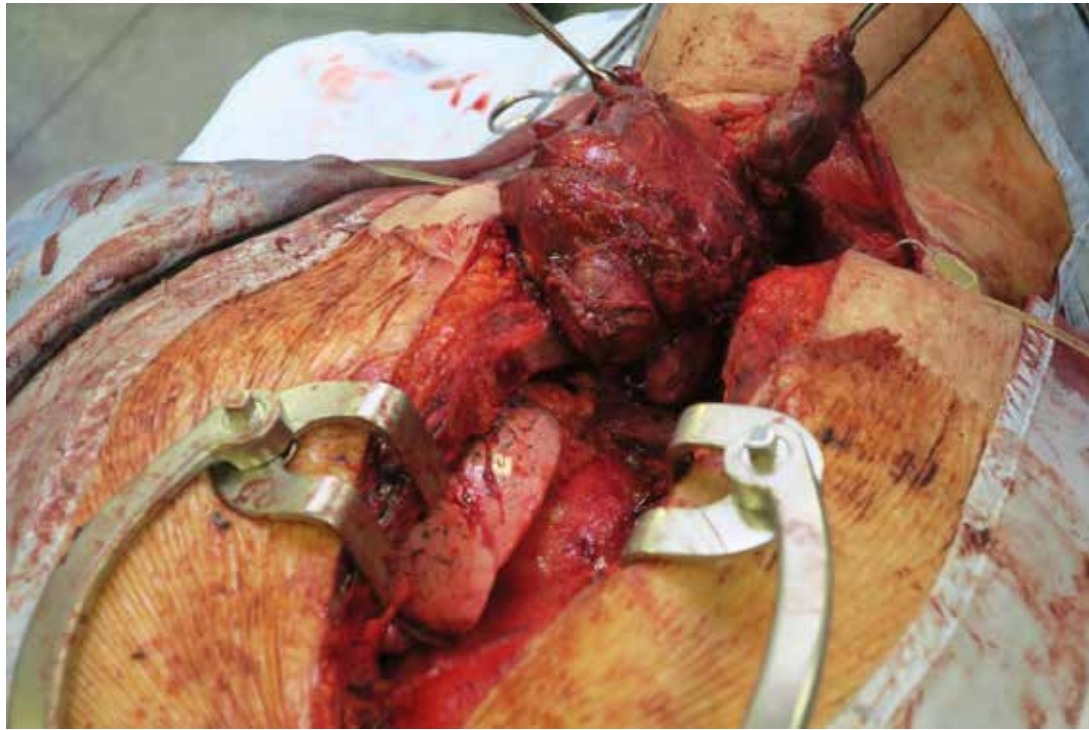- 64 years old driver
  - Increasing history of SOB/OE
  - CXR – Upper mediastinal shadow
  - USS guided FNAC – Thy 3f – Bethesda 4
- 
- Upgraded to Thy 4 Bethesda 5 – Any other investigations?
  - Cross Sectional Imaging?



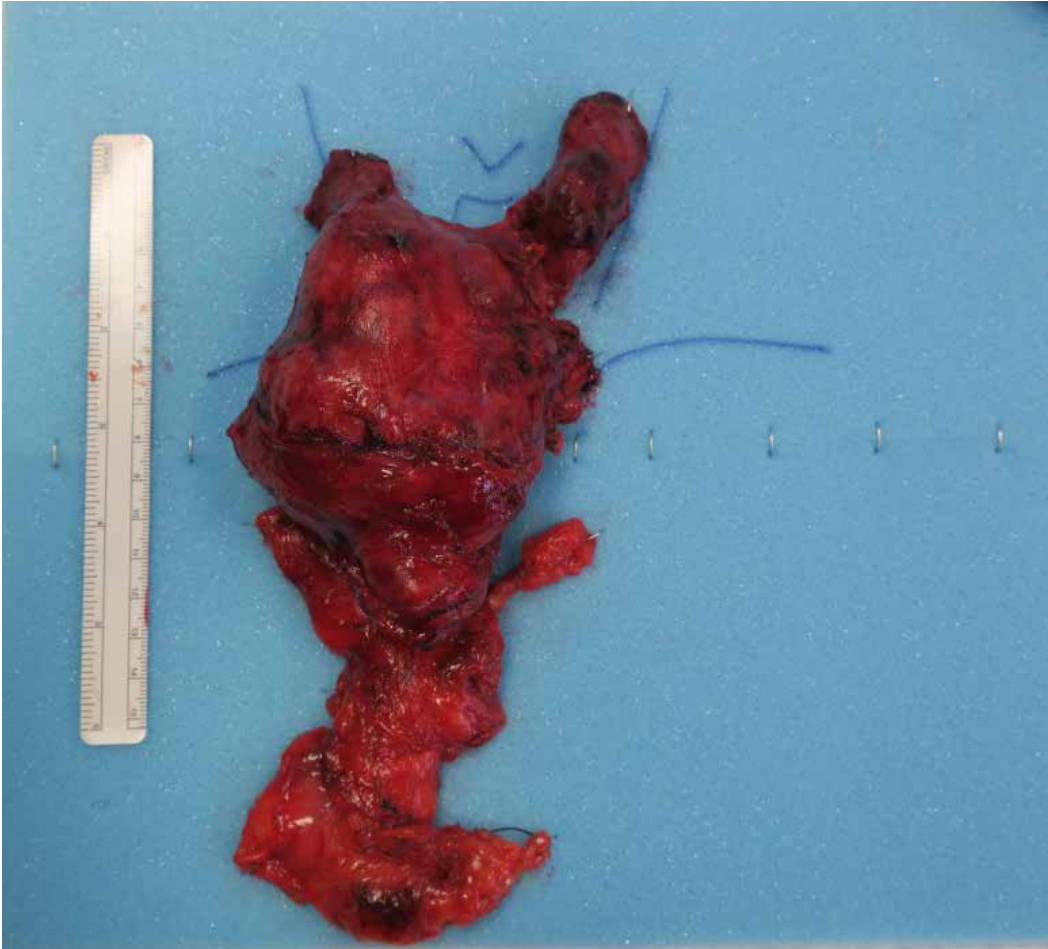
# Case 4



# Intraoperative Findings



# Postoperative findings



# Histopathology

- Histology: Conventional T4 N1b R1????? Follicular variant Papillary Thyroid Carcinoma
- What next?
  - RIA Dose?
  - PORT? Dose?

# Clinical Case 5

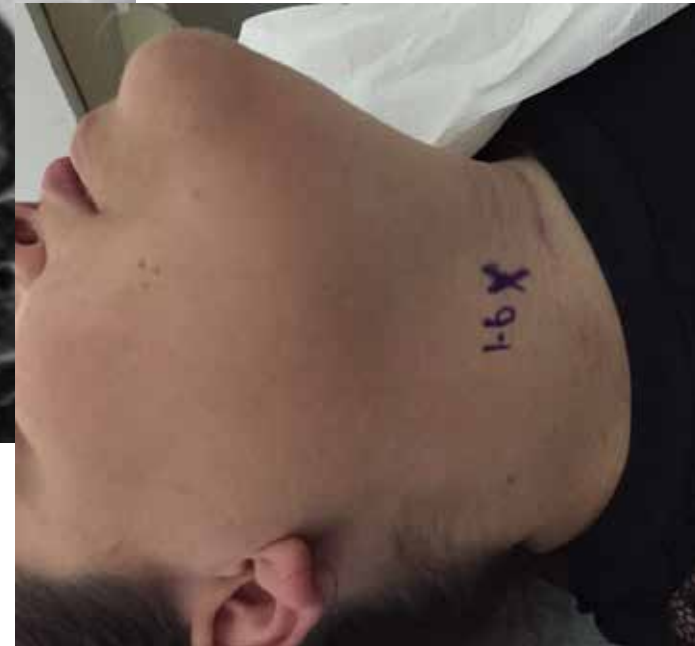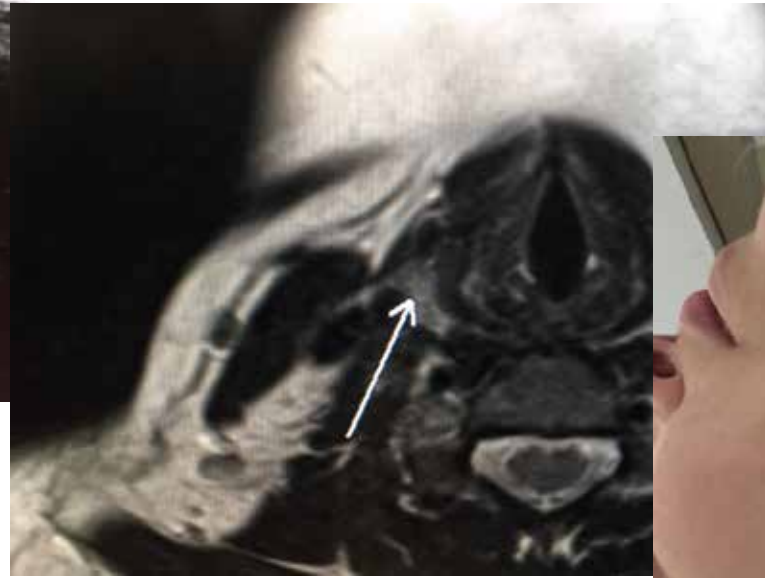
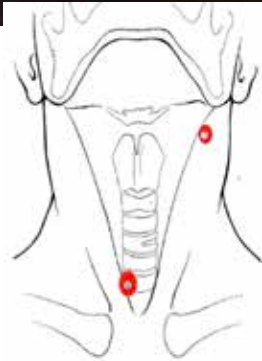
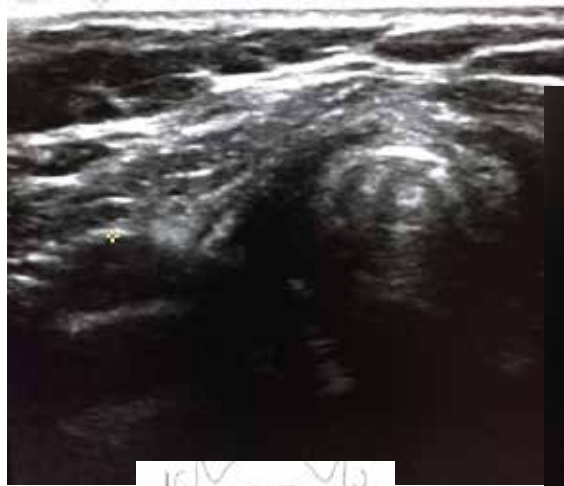
# Clinical Summary 5

- 27 years old project manager
  - T2N0M0 PTCa treated with Total Thyroidectomy and RIA
  - Raising thyroglobulin both non-stimulated and stimulated
  - USS guided FNAC – Recurrence right thyroid bed
  - Revision surgery – Fat
  - Would like a second opinion
- 
- How we should investigate her? CT, MRI, PET

# Preoperative Mapping

## “Strategic Mapping Plan”

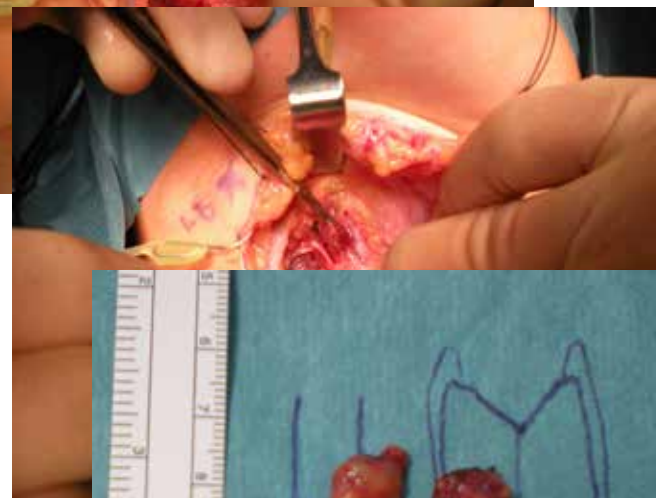
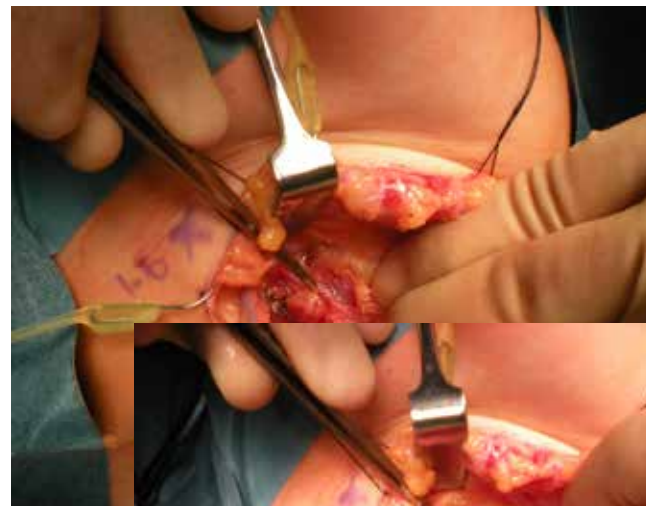
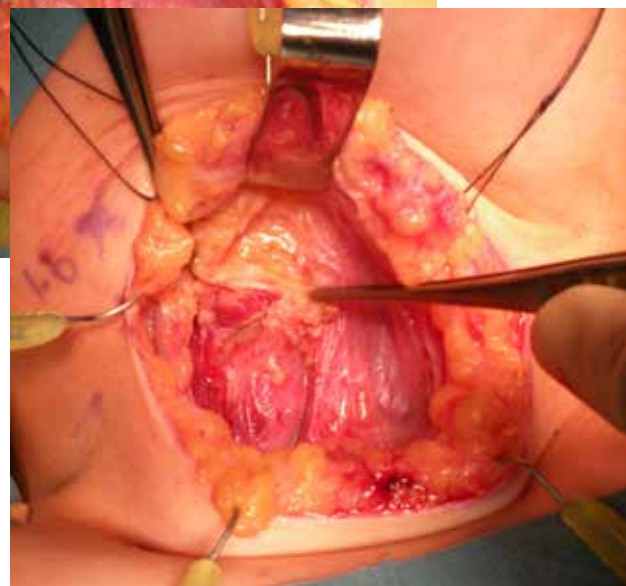
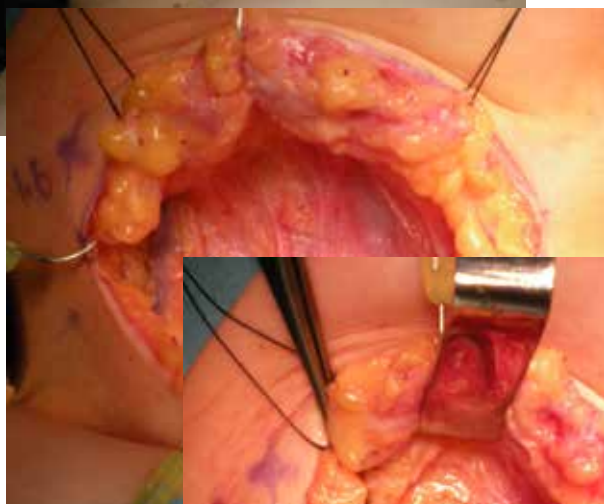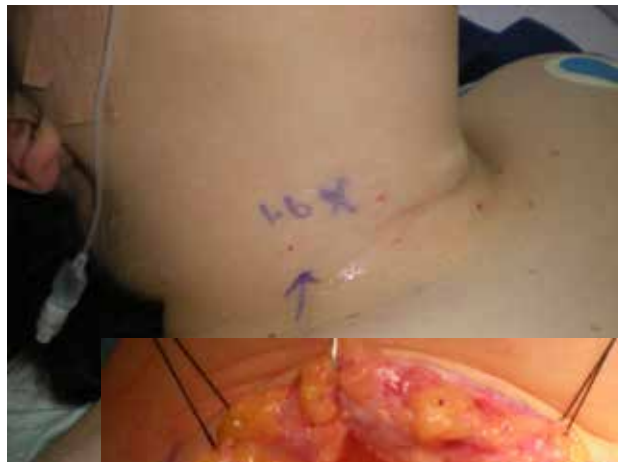- Done with USS by Radiologist or Surgeon
- Mark the site and indicate depth - **Intraoperative USS**



*Scharpf et al Head & Neck 2016*



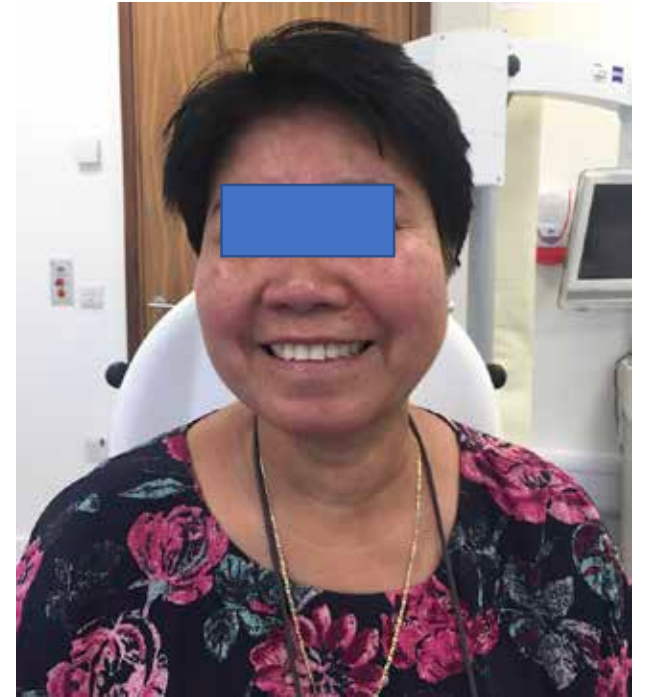# Targeted Approach – How?



# Clinical Case 6

# Clinical Summary

- 57 years old nurse from Malaysia.
- Short history of thyroid mass, with SOBOE
- PMH: Mitral valve prolapse and CVA
- ECoG: 1
- Smoking: Non-smoker
- Alcohol: 14 units a week
- SH: Lives with husband
- Fibreoptic laryngoscopy shows left vocal cord palsy

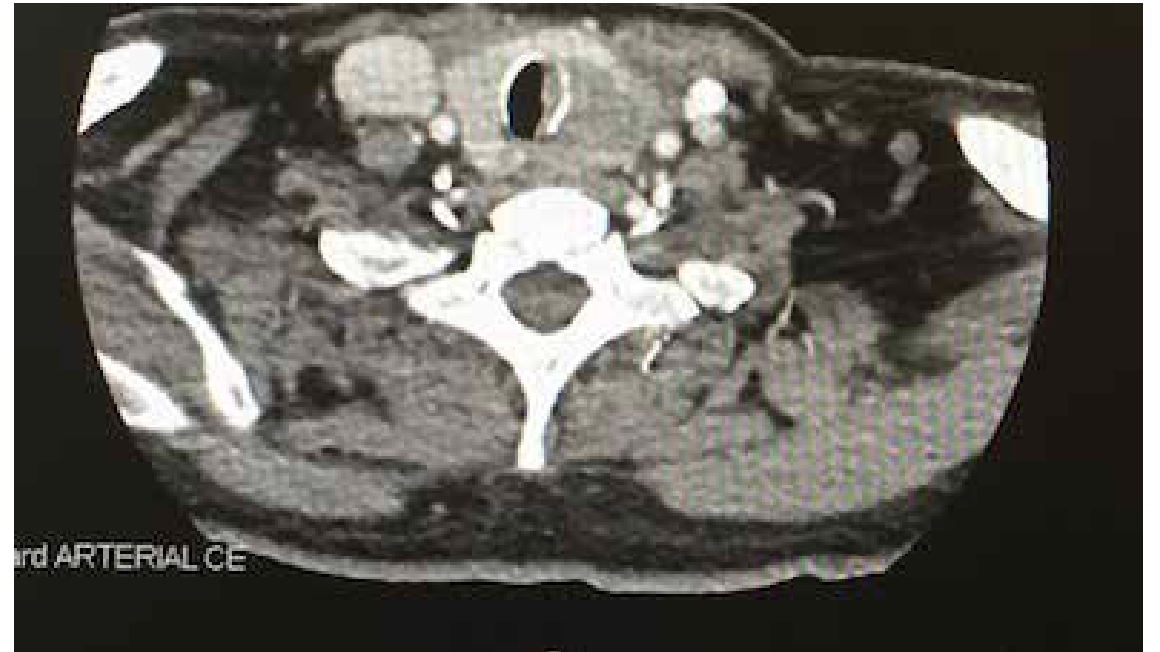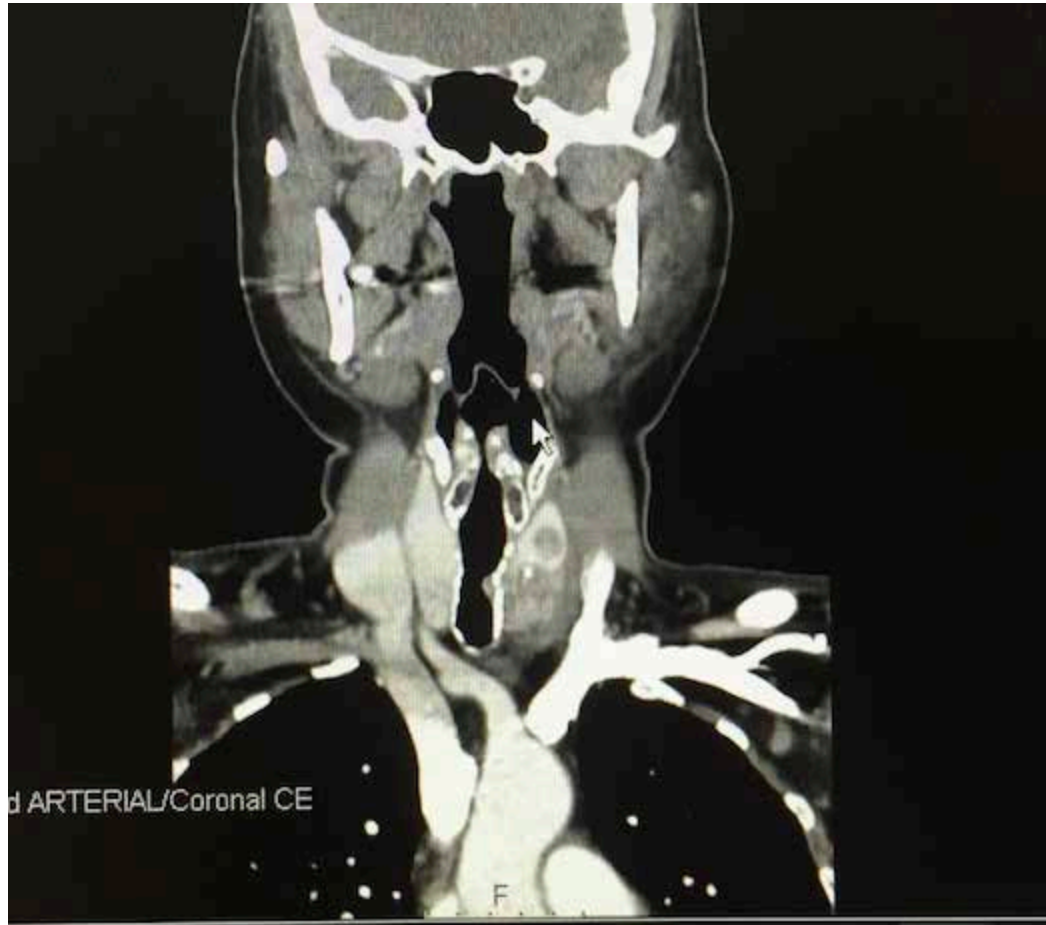


# Clinical Findings

- cT4
- cN0
- cMx

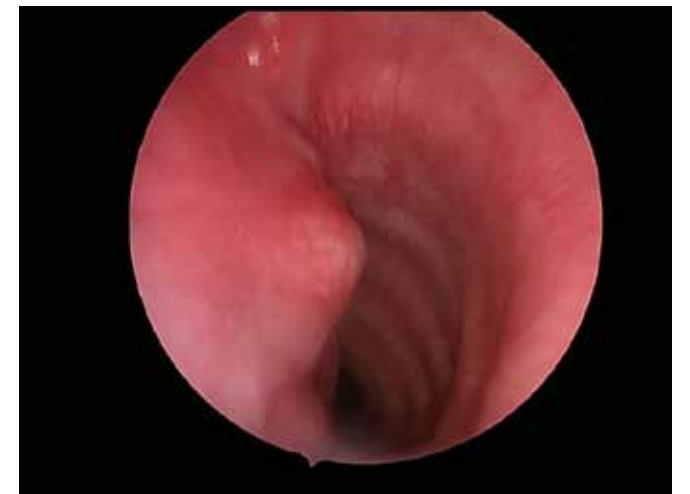
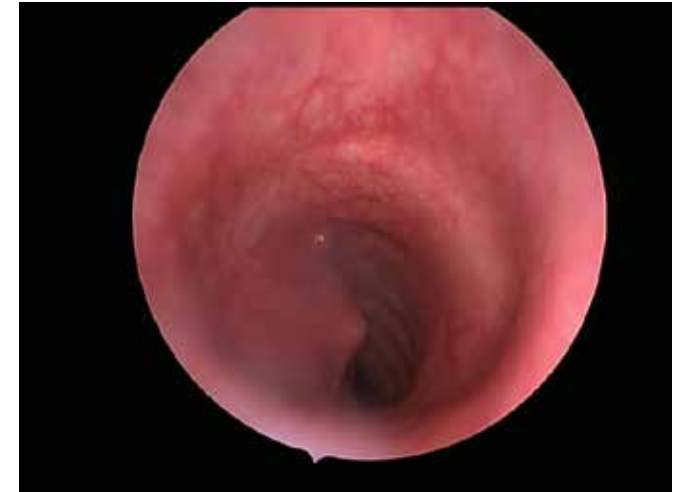
# Investigations?

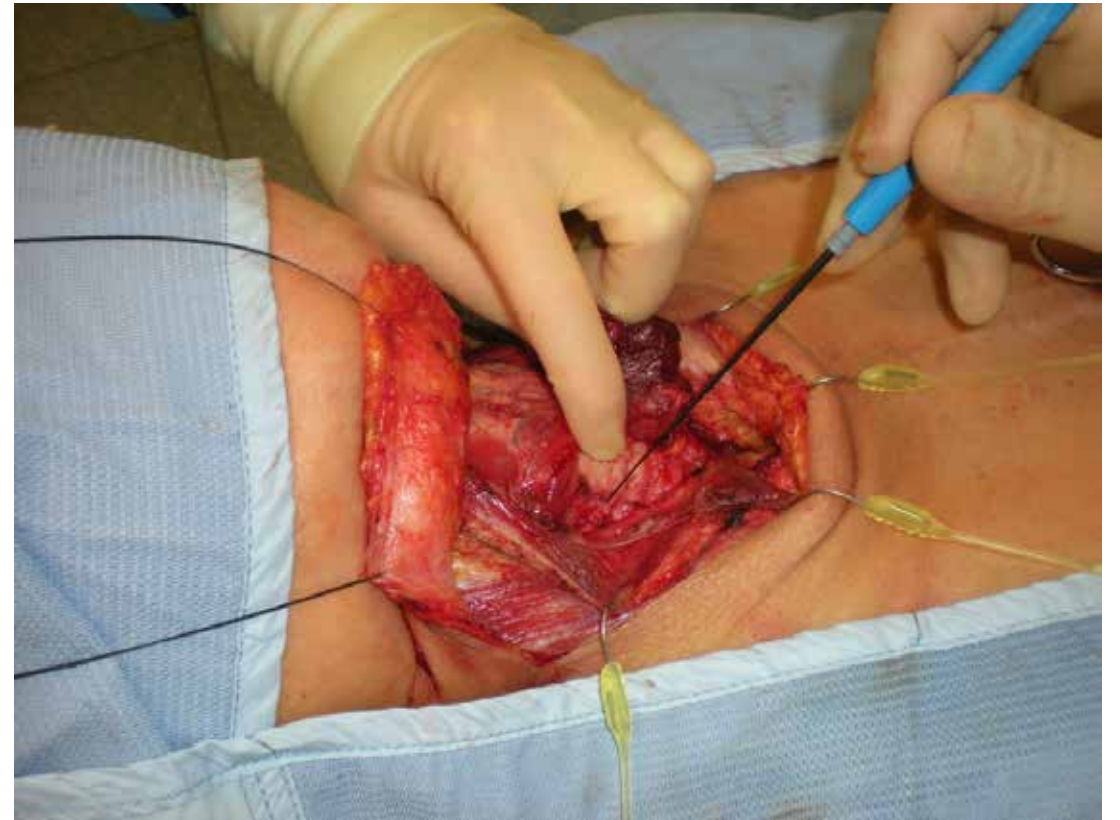
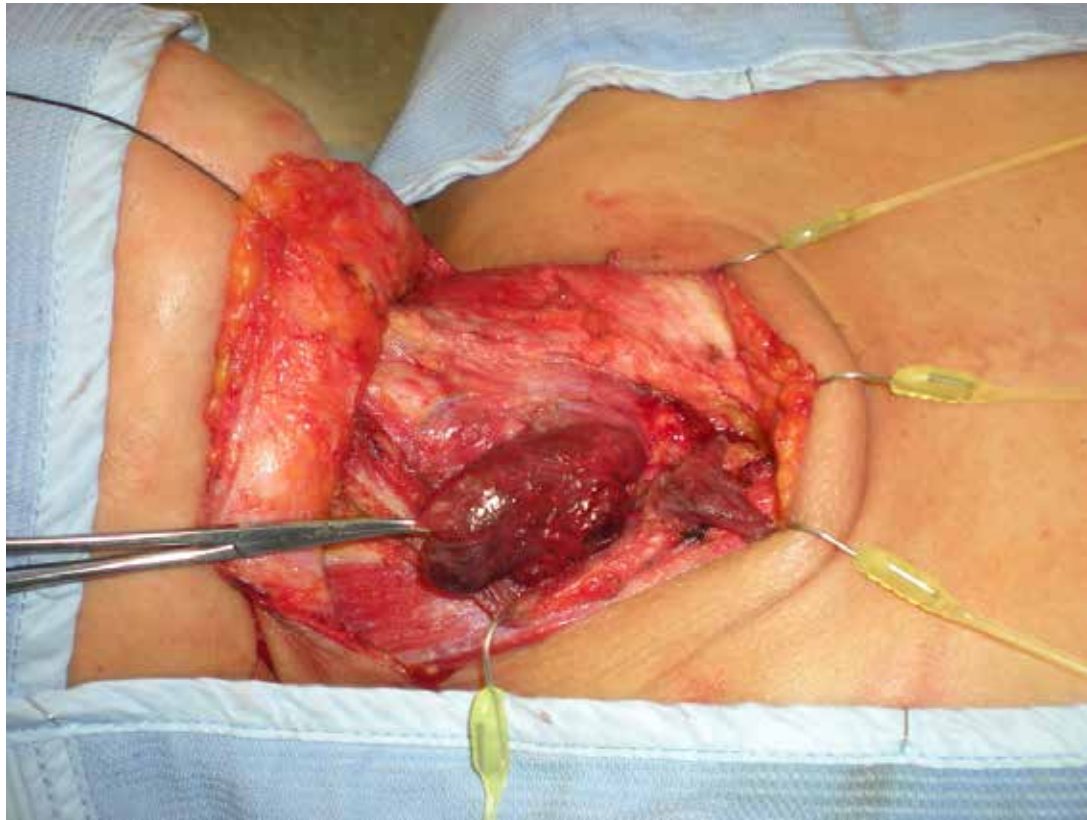


# Clinical Findings - Panendoscopy

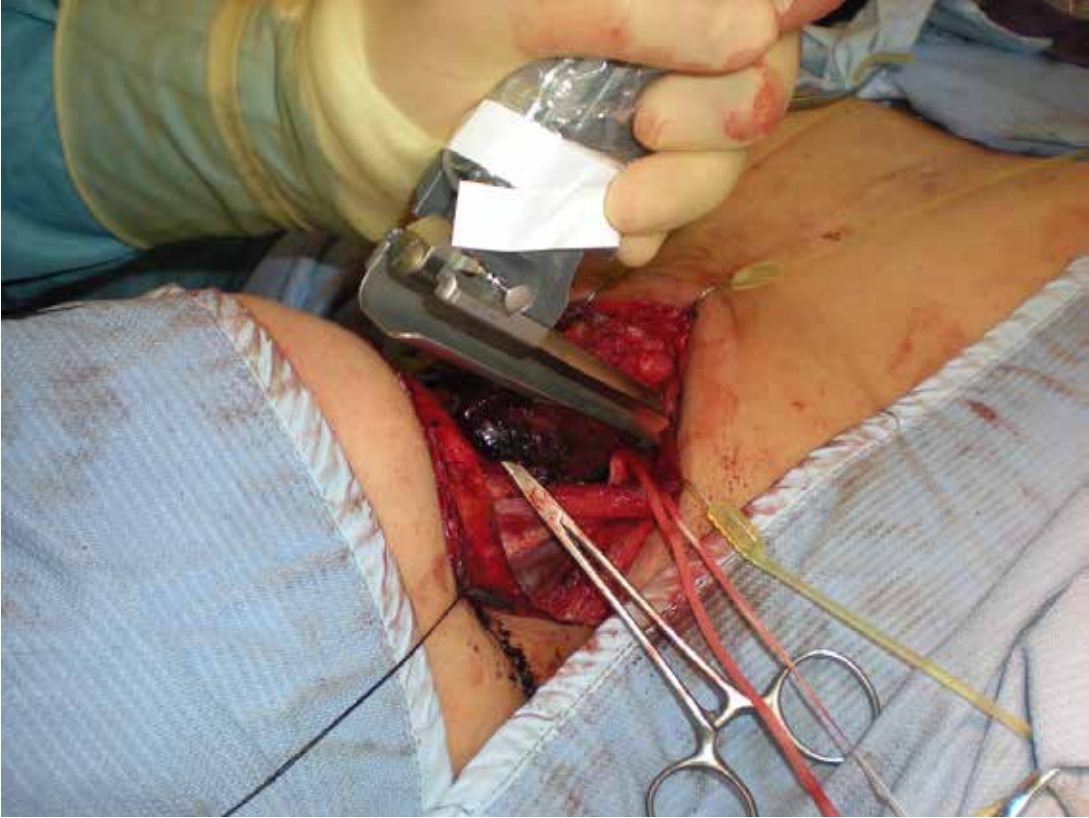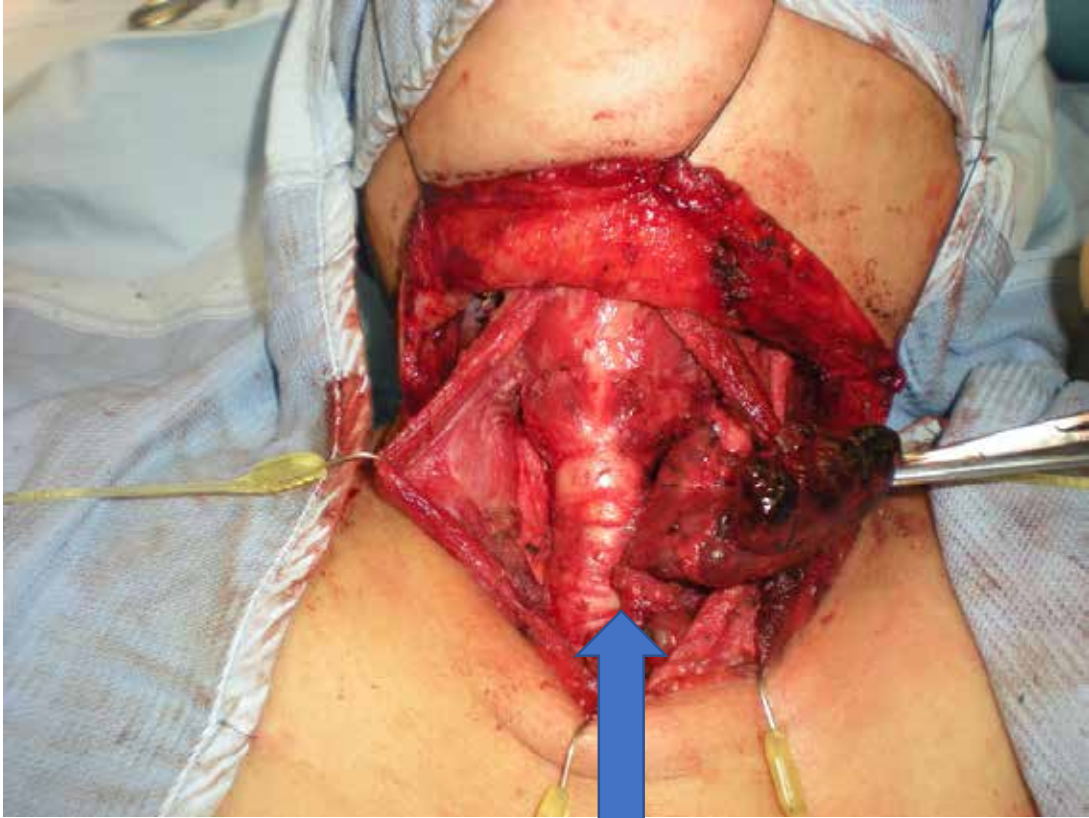
- cT4
- cN0
- cMx



# Surgical Resection – Approach

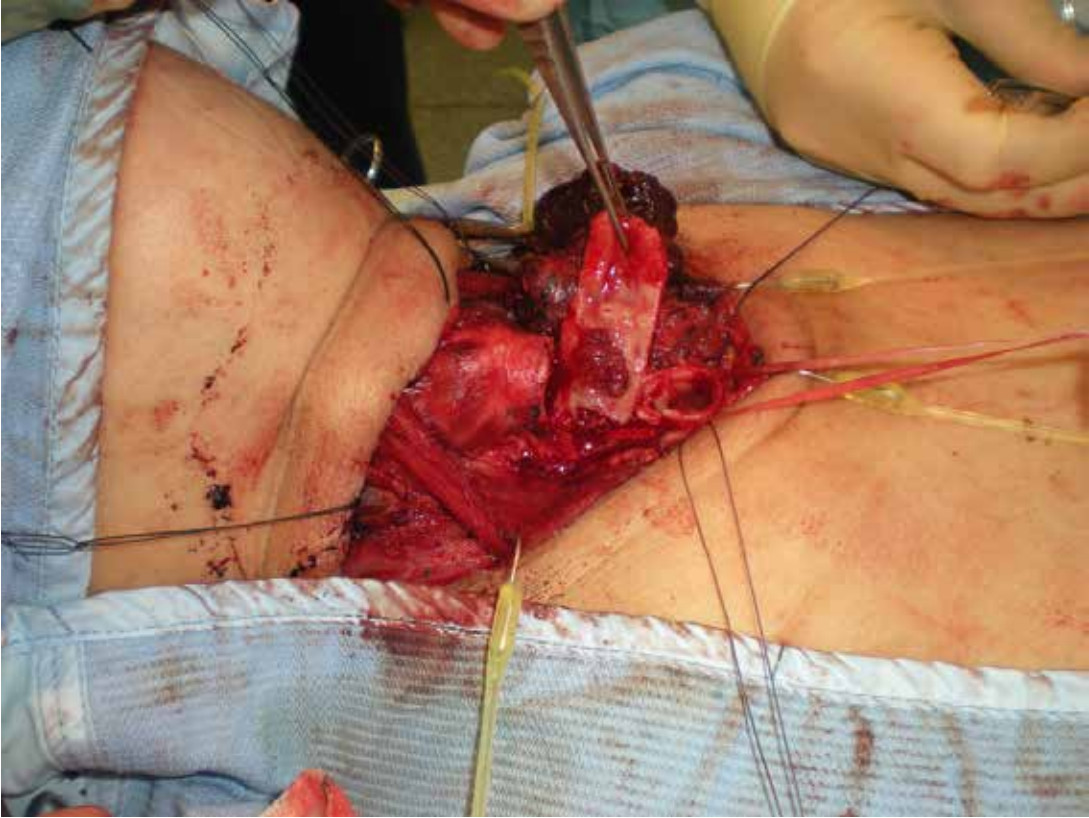
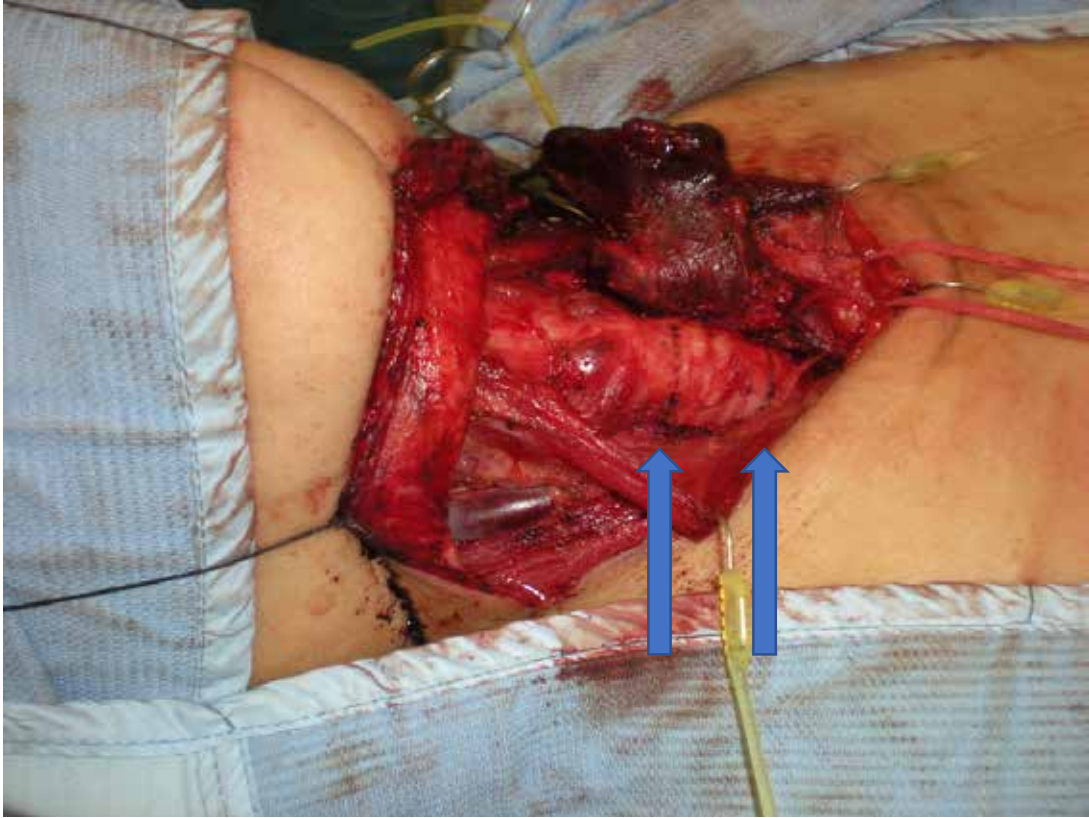
# Surgical Resection – Mediastinal Exploration

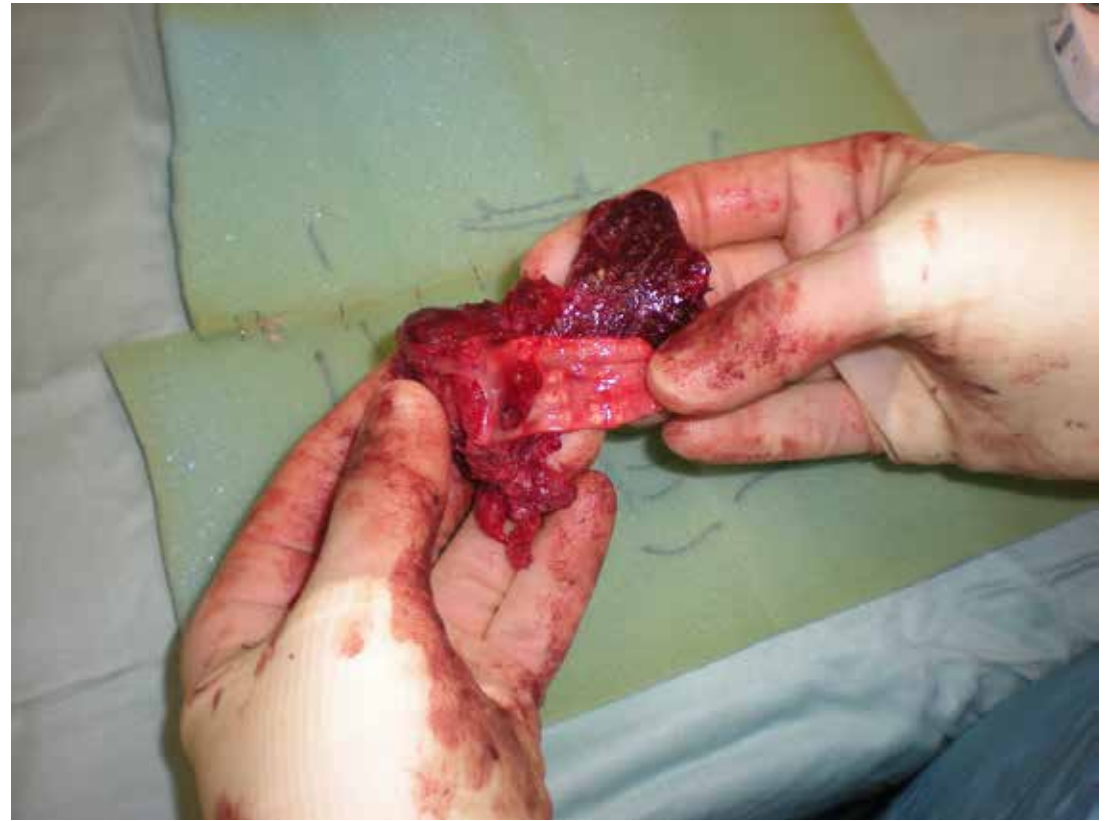
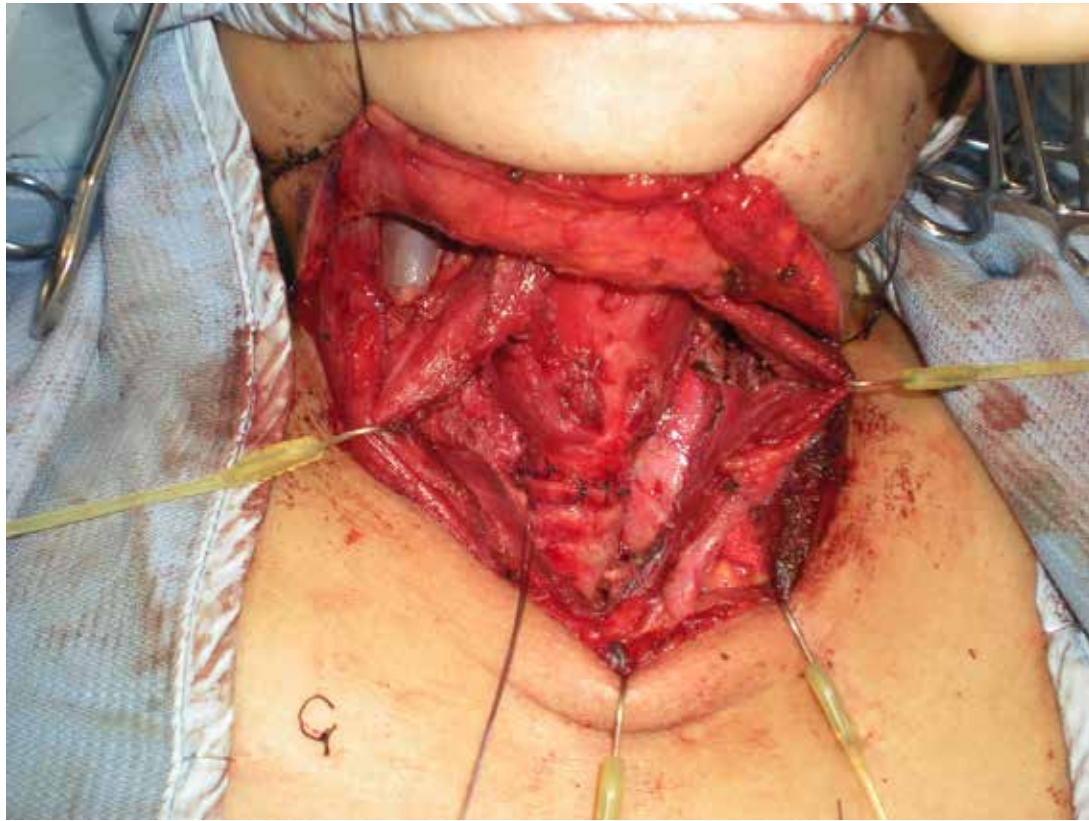




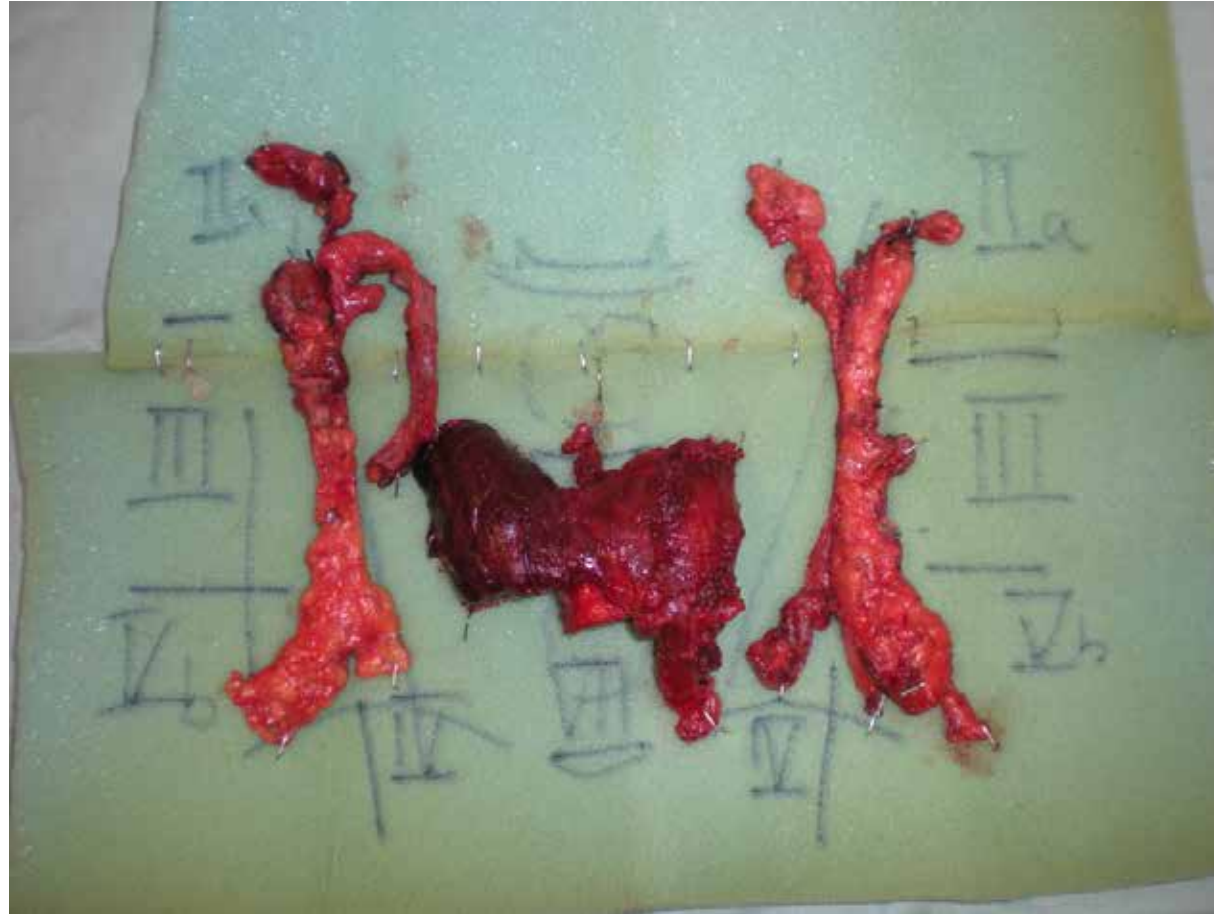
# Surgical Excision – Tracheal Resection



# Tracheal Reconstruction

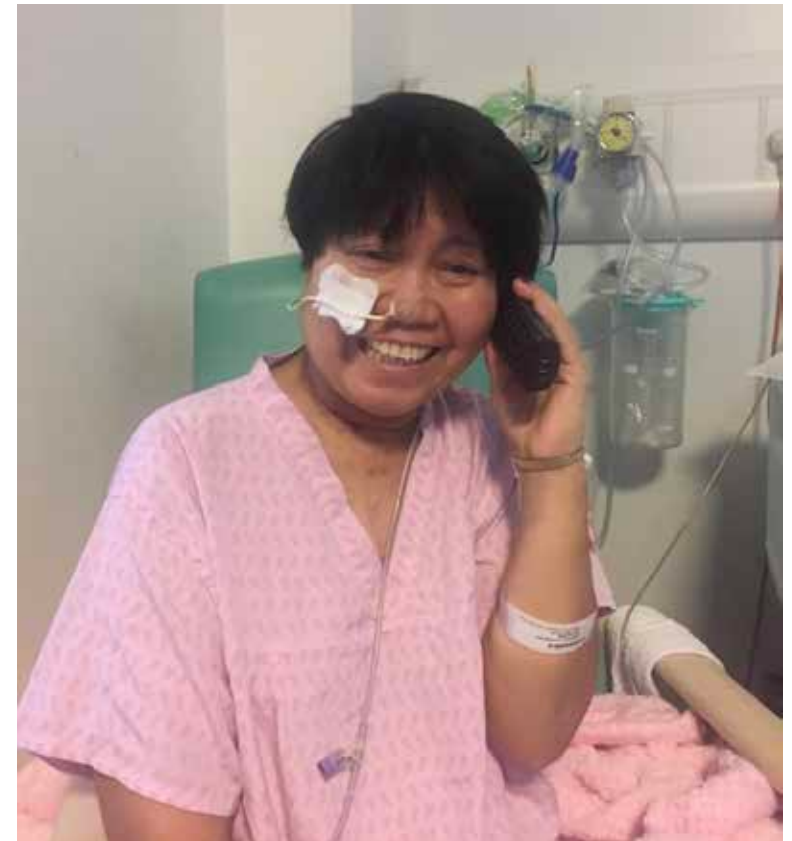

# Histopathological Specimen



# Management Plan

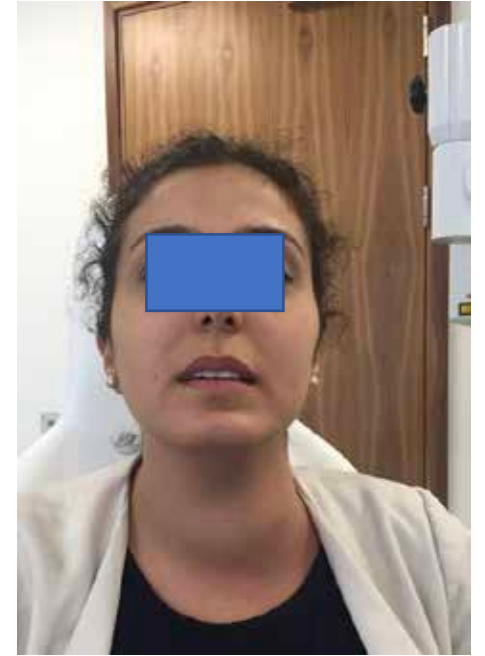- Histopathology: Poorly differentiated thyroid Carcinoma:
  - 25% well differentiated
  - 50% Tall cell variant
- Advice on adjuvant therapy?



# Clinical Case 7

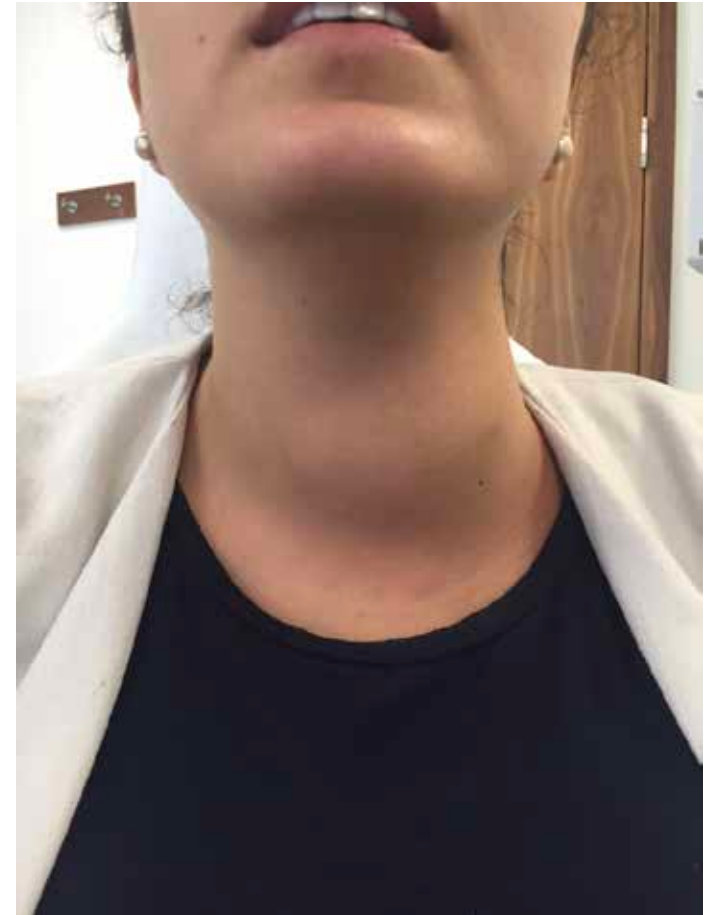
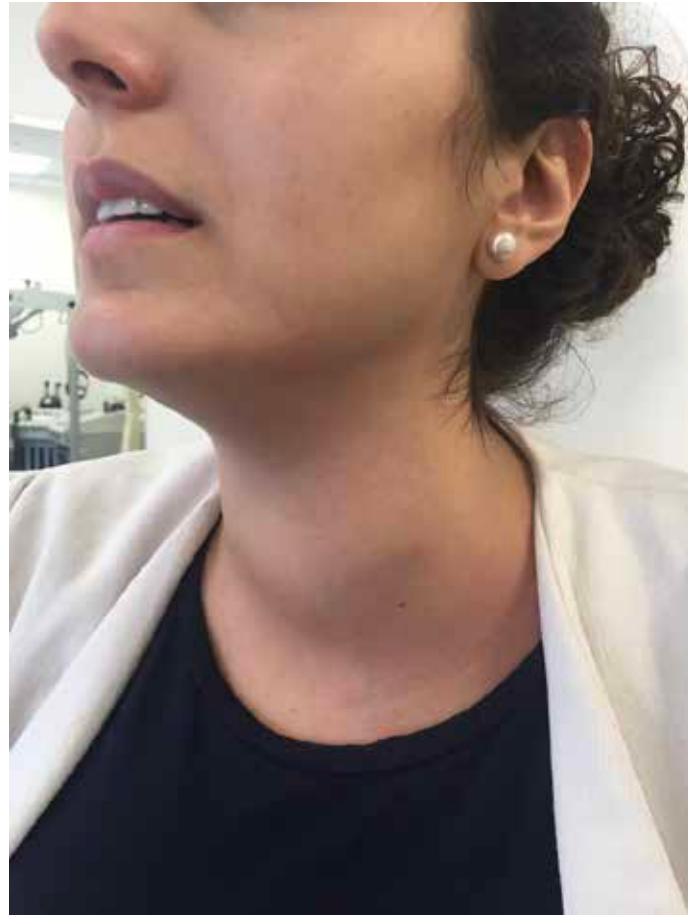# Clinical Summary

- 34 years old originally from Lebanon who works in finance
- 3/12 history of thyroid mass increasing in size causing pain and associated with B symptoms
- USS FNAC/CNB: PDTCa with neck metastases
- Anaemia and raised WCC, ESR and LDH – Seen Paul Fields
- PMH: None
- ECoG: 0
- Smoking: Non-smoker
- Alcohol: 14 units a week
- SH: Lives with family



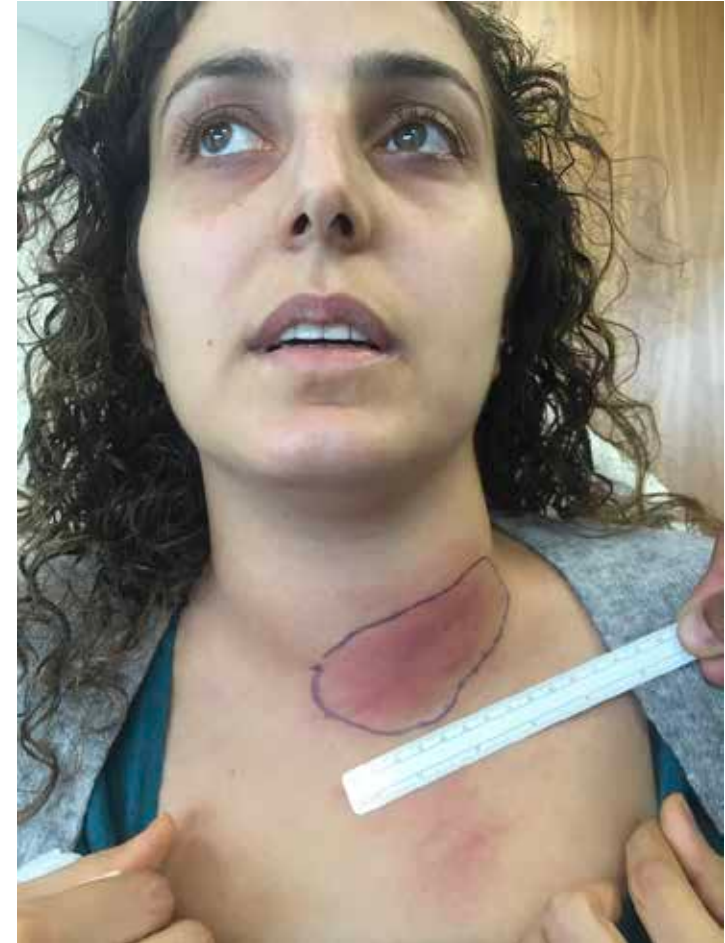# Clinical Findings October 2018

- cT4
- cN1b
- cMx



# Clinical Findings November 2018

- cT4
- cN1b
- cMx





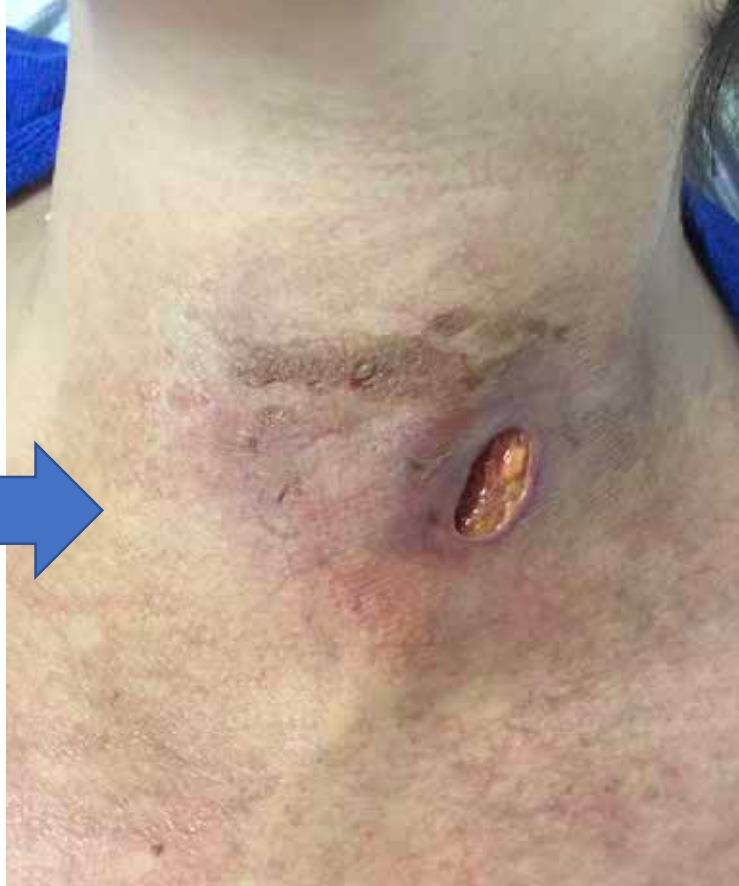
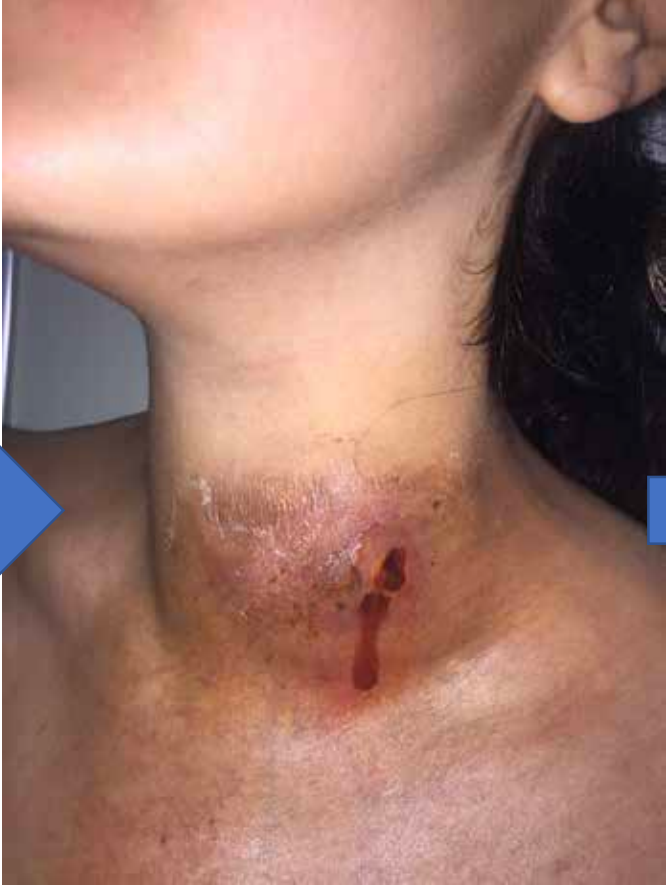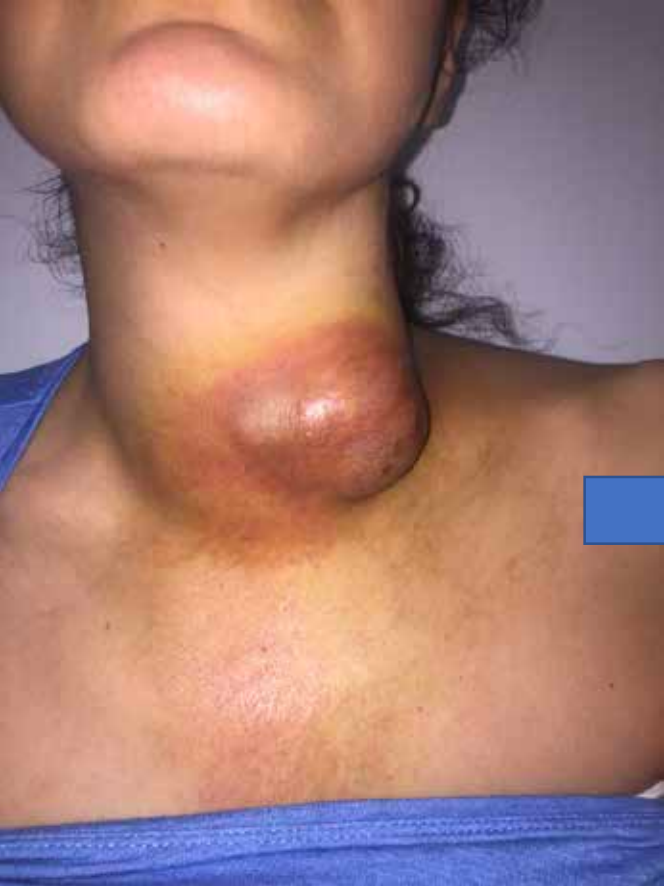# Management Plan

- Review Histopathology and recent CT scans
- PET-CT
- Discuss further management in view of recent changes in the skin and rapid tumour progression

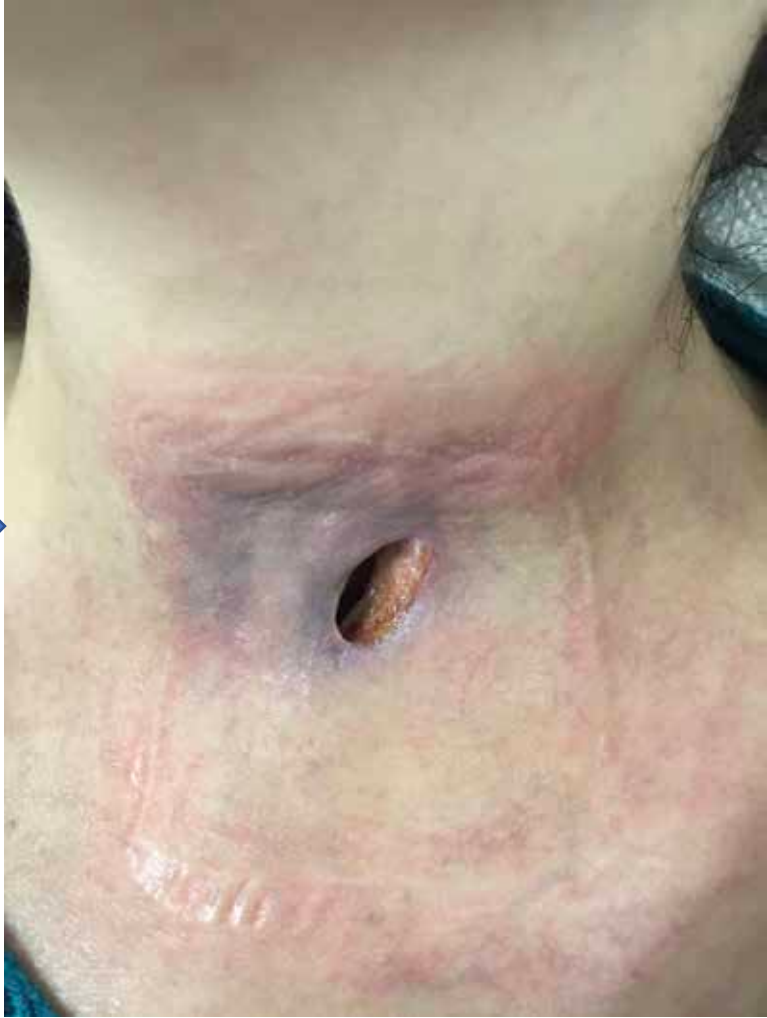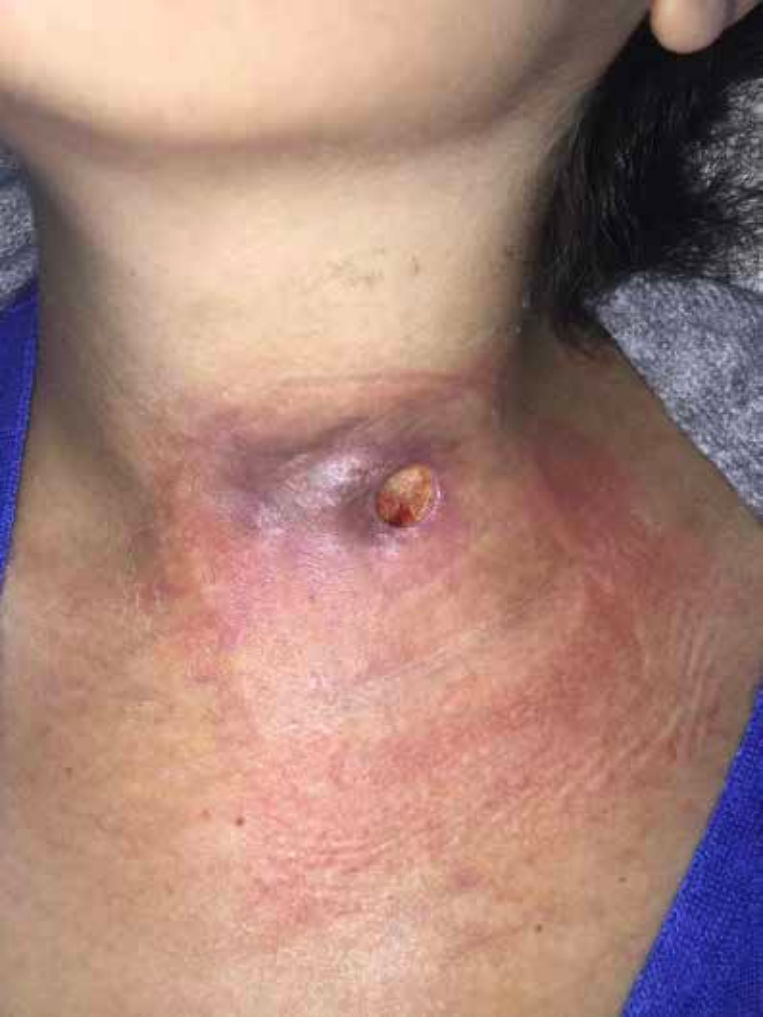# Current Treatment

- Vendetanib 24 mg daily
- Thyroxine 125 micrograms daily
- Ferrous Fumarate
- Daily dressings

# Clinical Progress – December 2018



# Clinical Progress – January 2019



# Management Plan

- What next?



**Thank you**