

Sessió de Residents

Acadèmia de Ciències Mèdiques

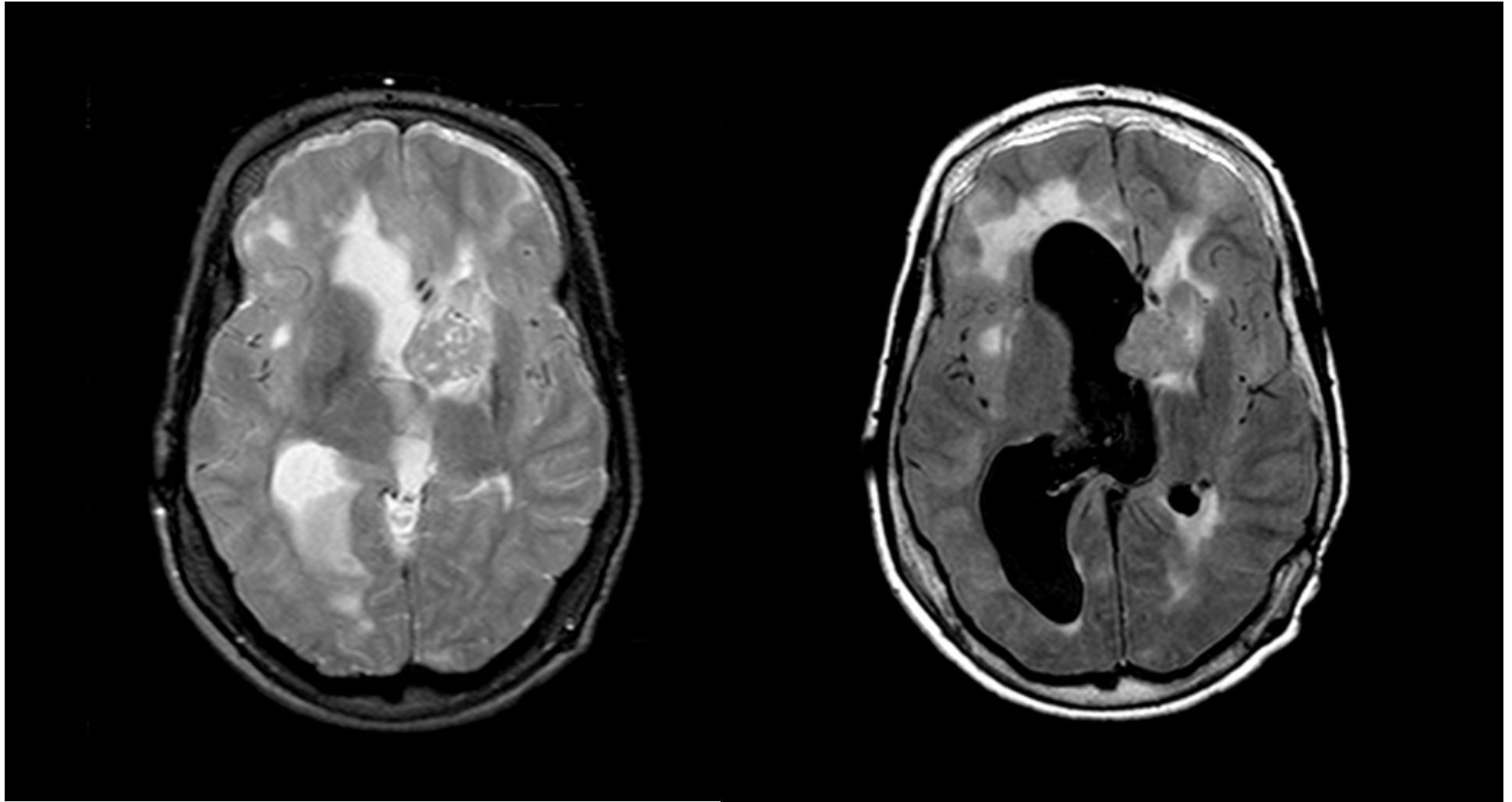


J. Alvaro Parra.
Hospital Universitari Germans Trias i Pujol

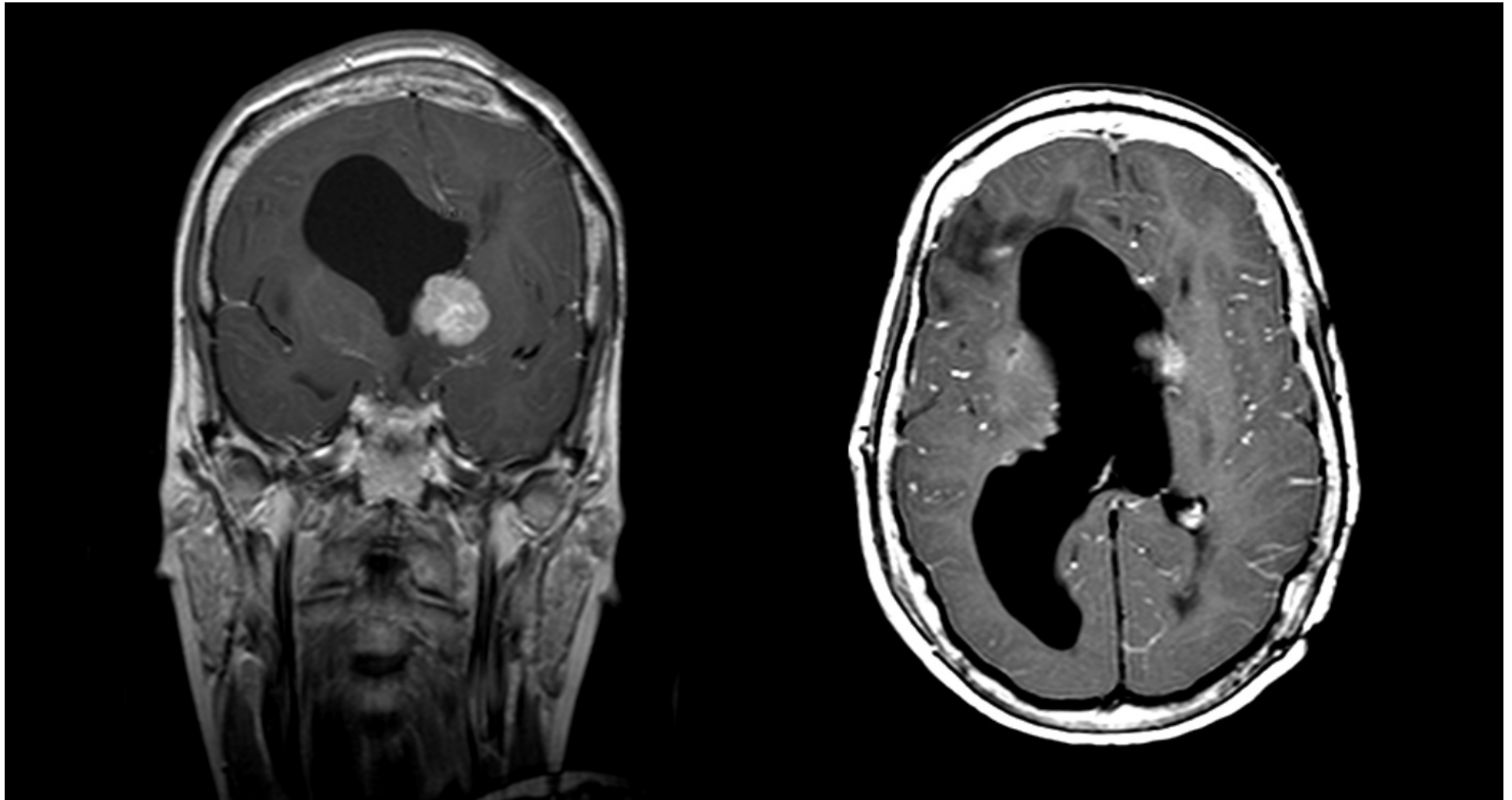
Historia Clínica

- Varón, 17 años de edad
- AP: Esclerosis Tuberosa (11 meses de edad)
- EA: 10 días de evolución:
Hemiparesia y disestesias de hemicuerpo izquierdo

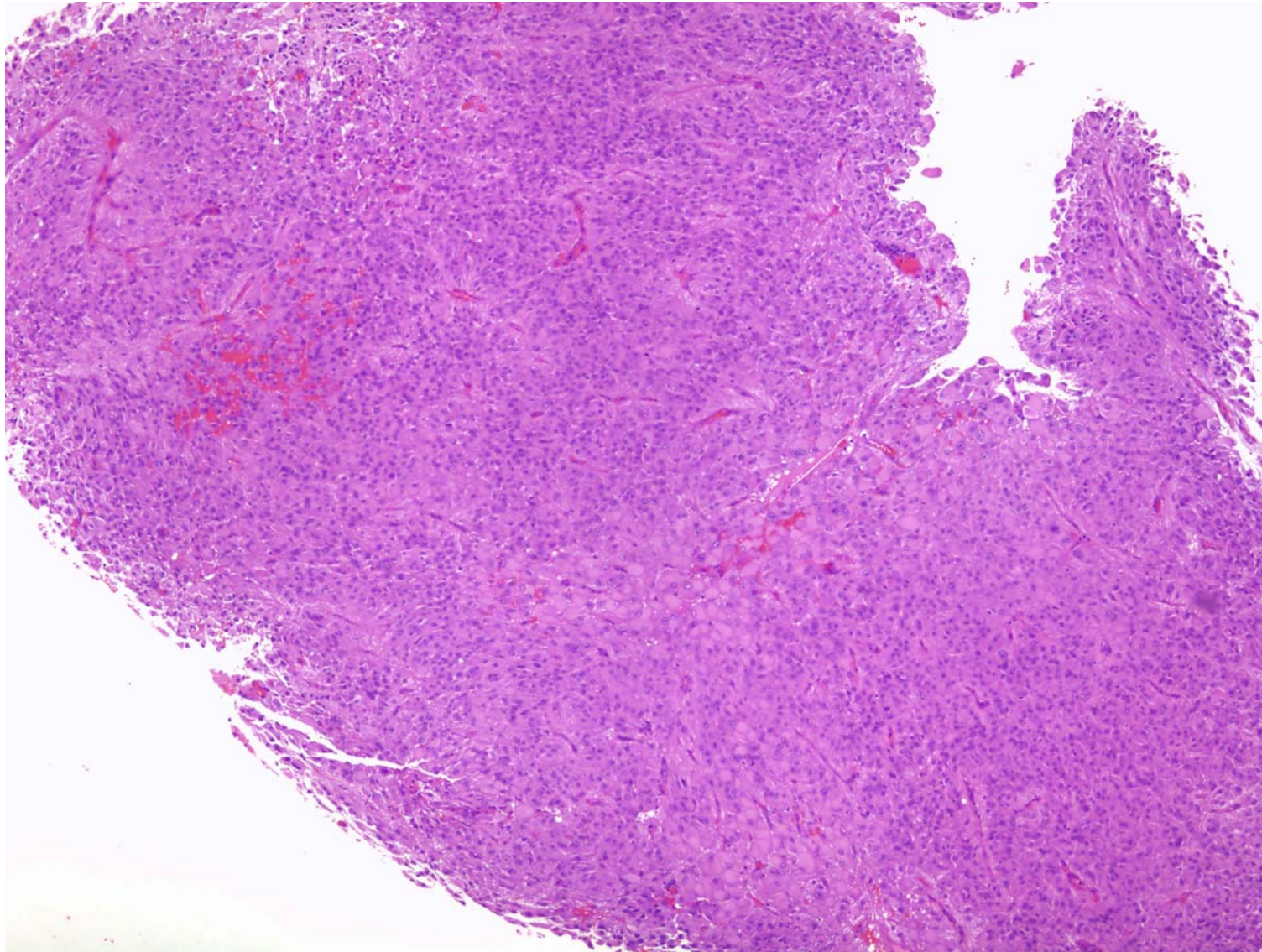
RMN

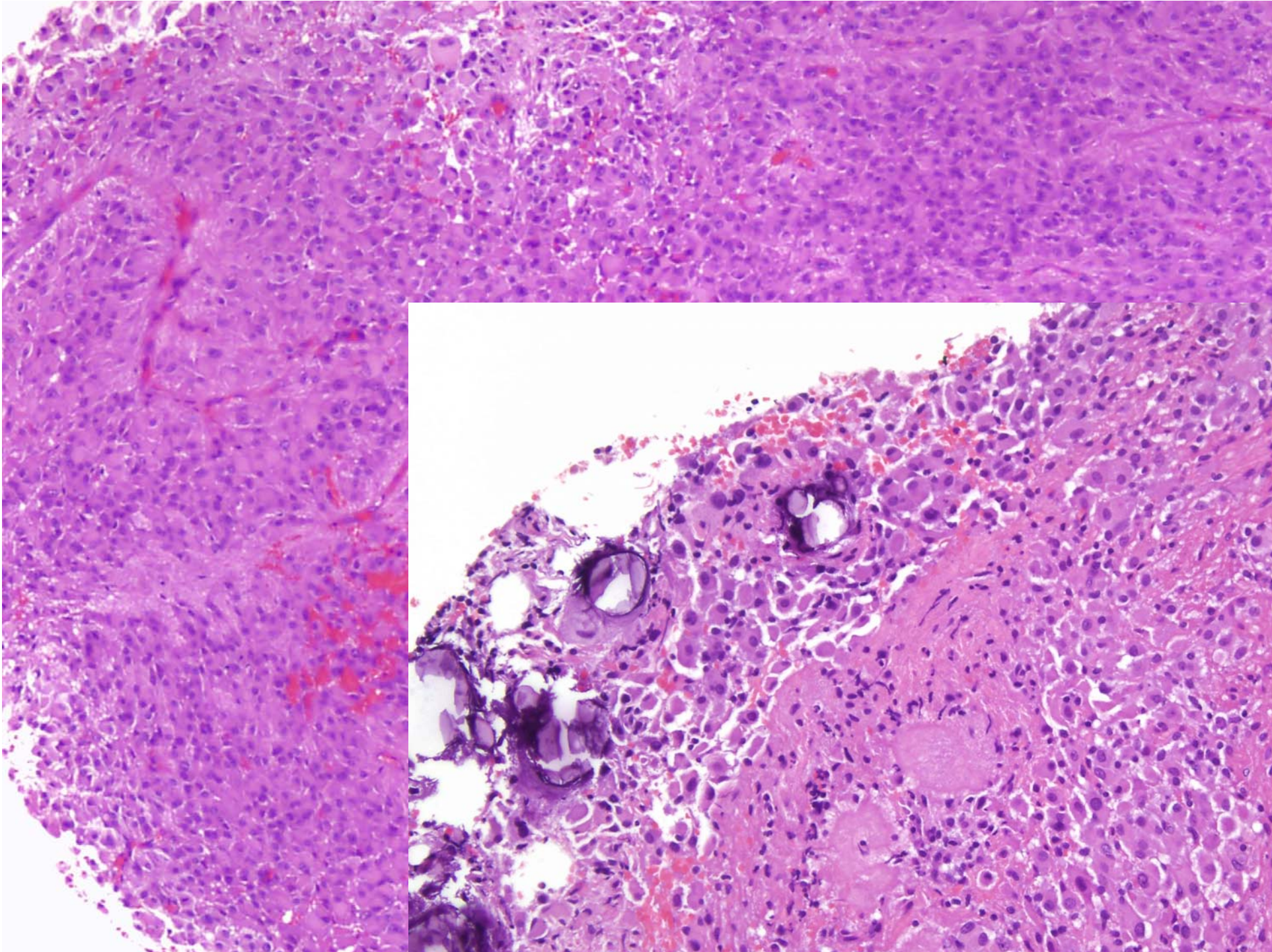


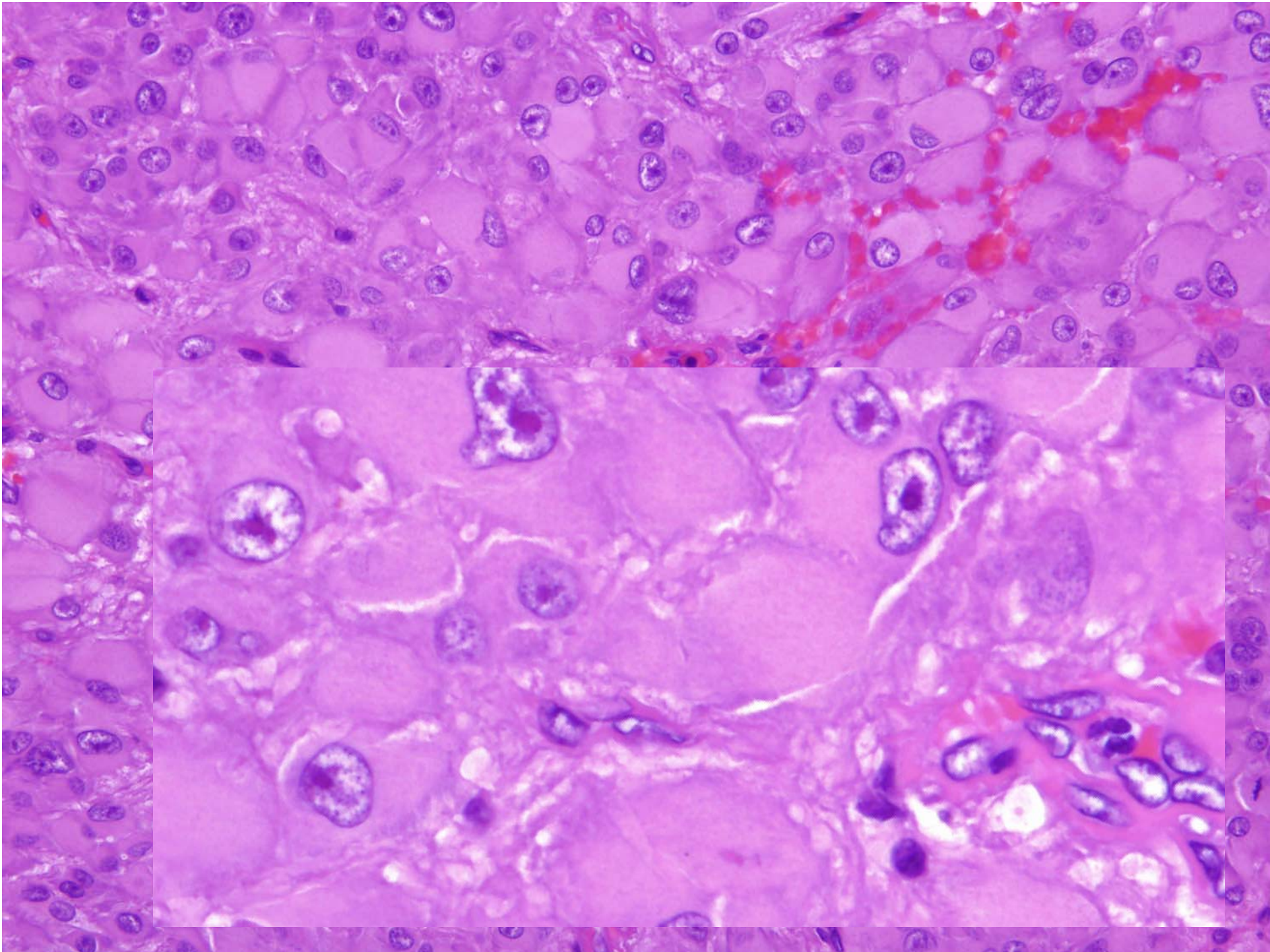
RMN

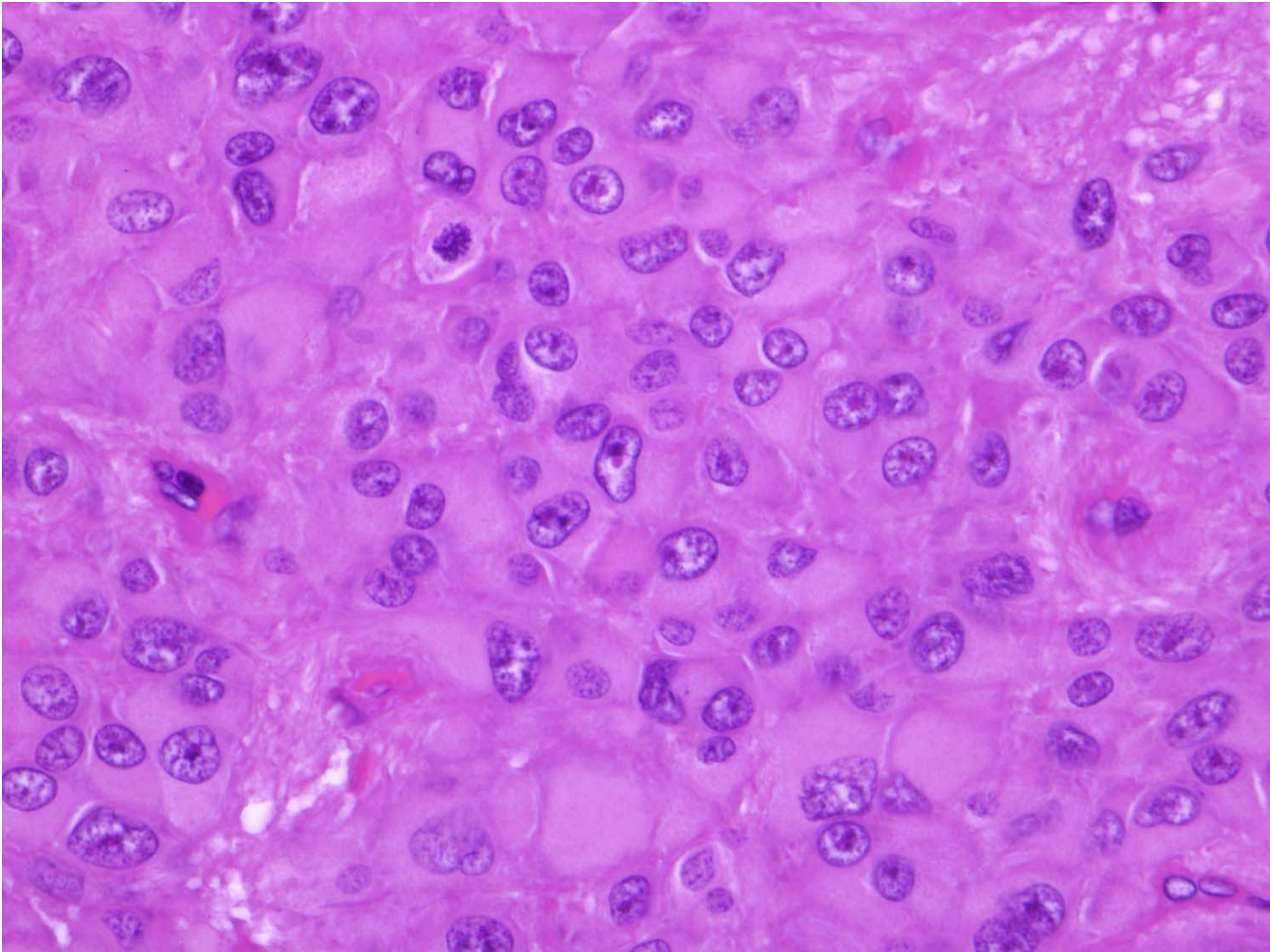


Histopatología

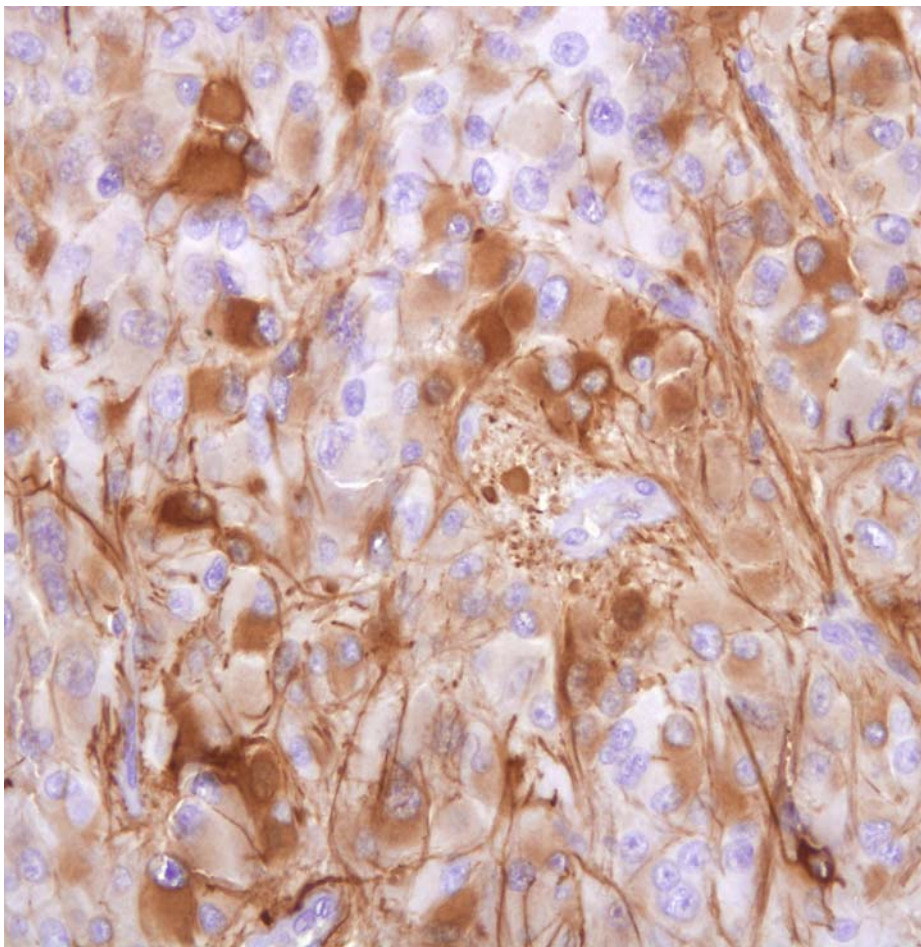




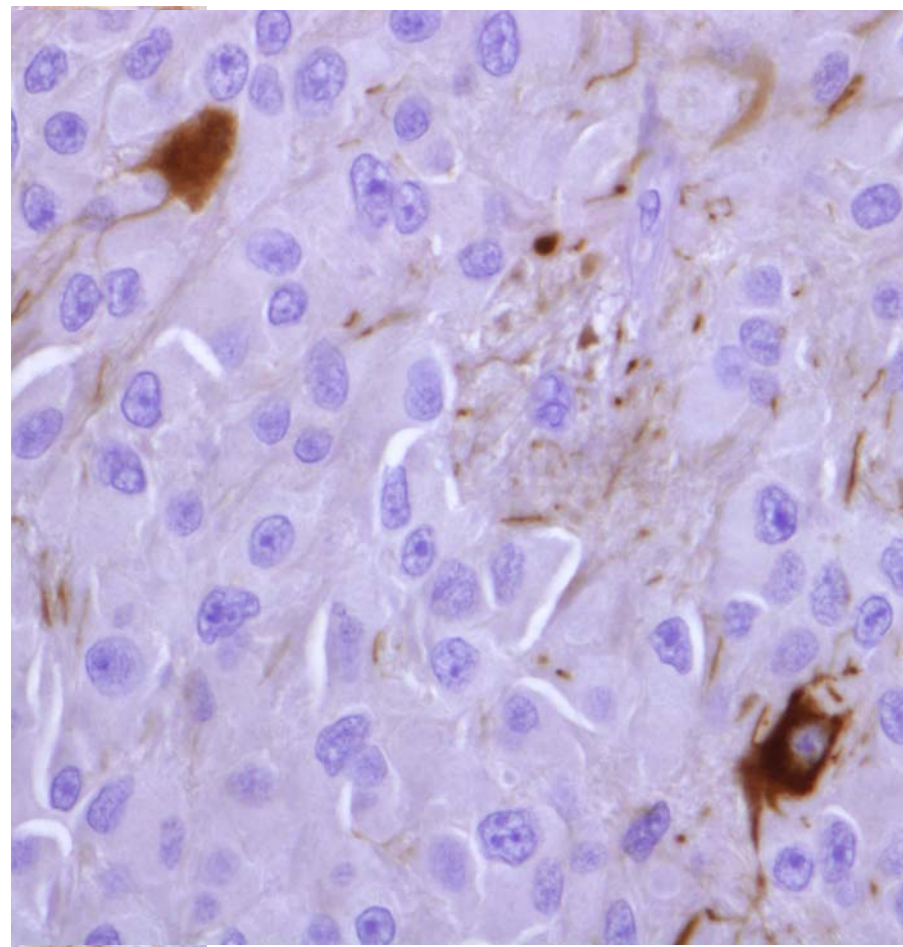




Inmunohistoquímica

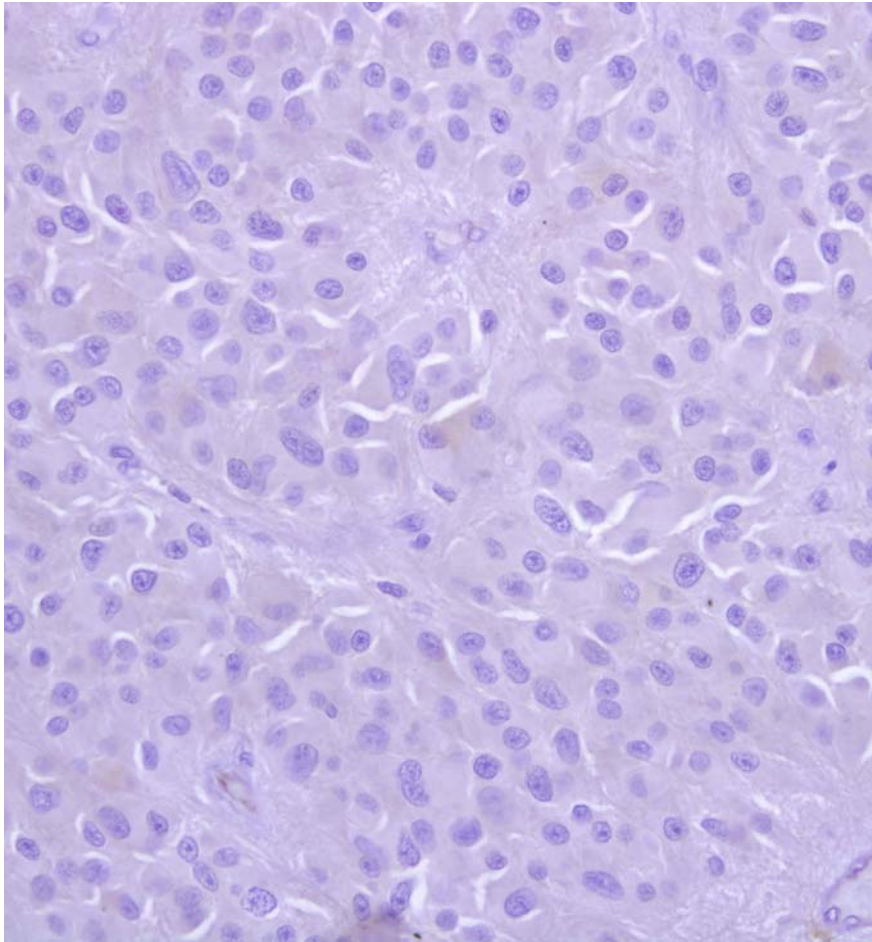


Proteína glial fibrilar ácida

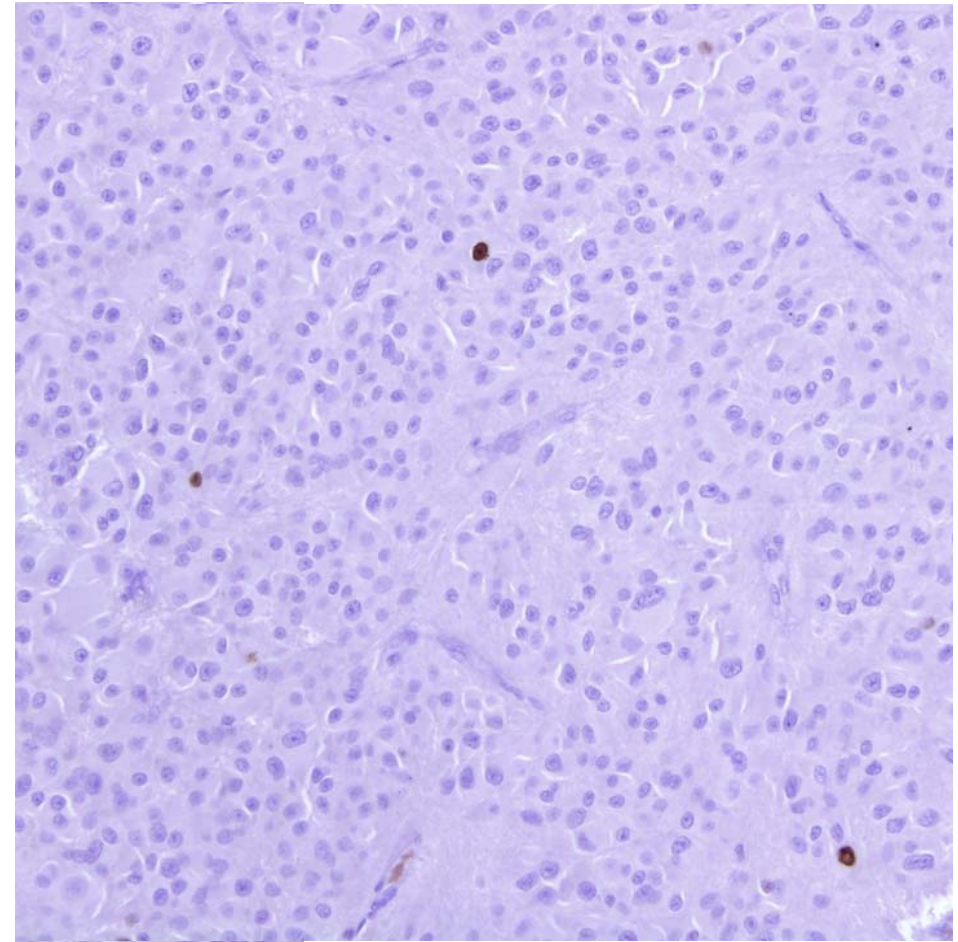


Neurofilamentos

Inmunohistoquímica



IDH1

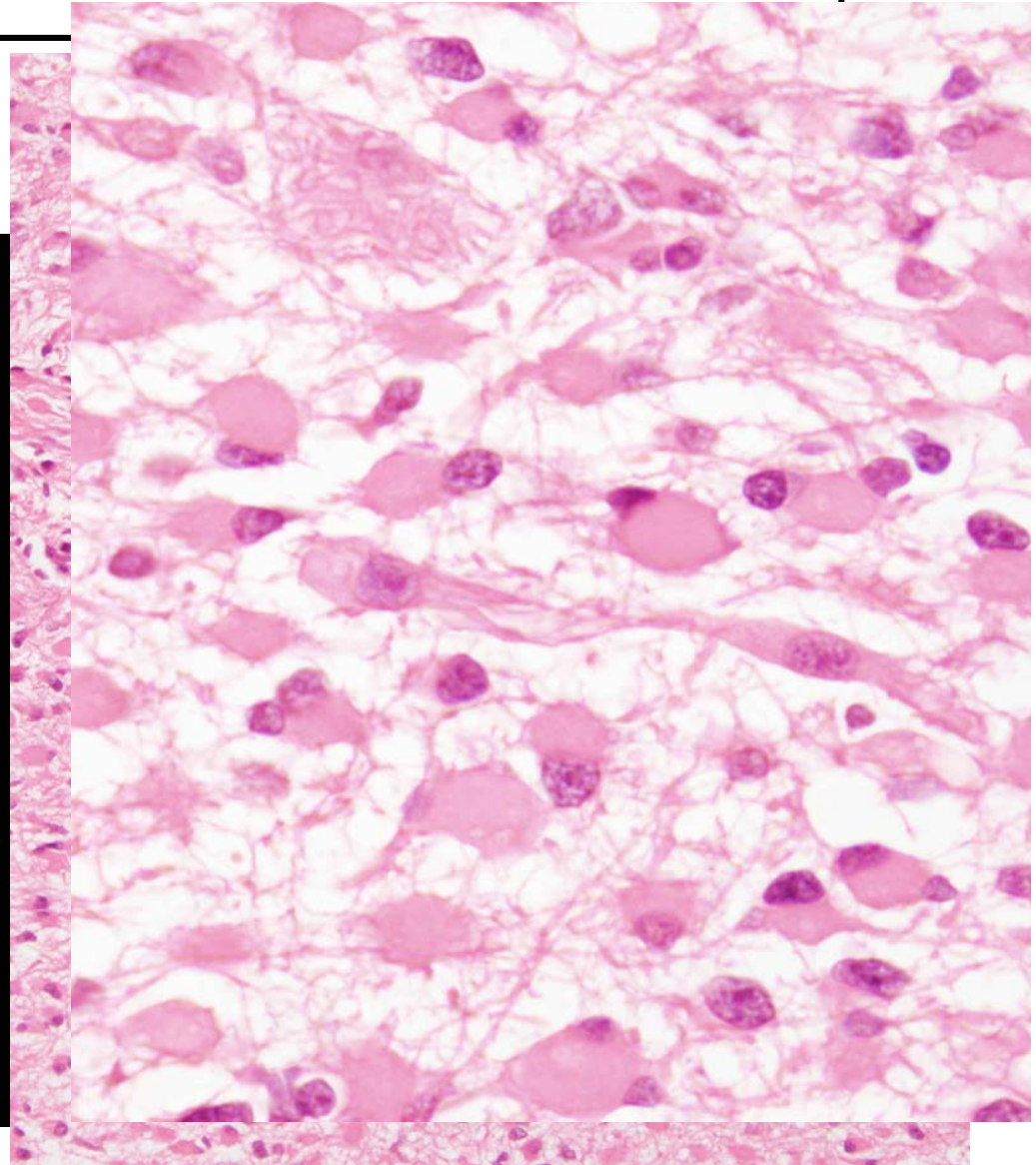
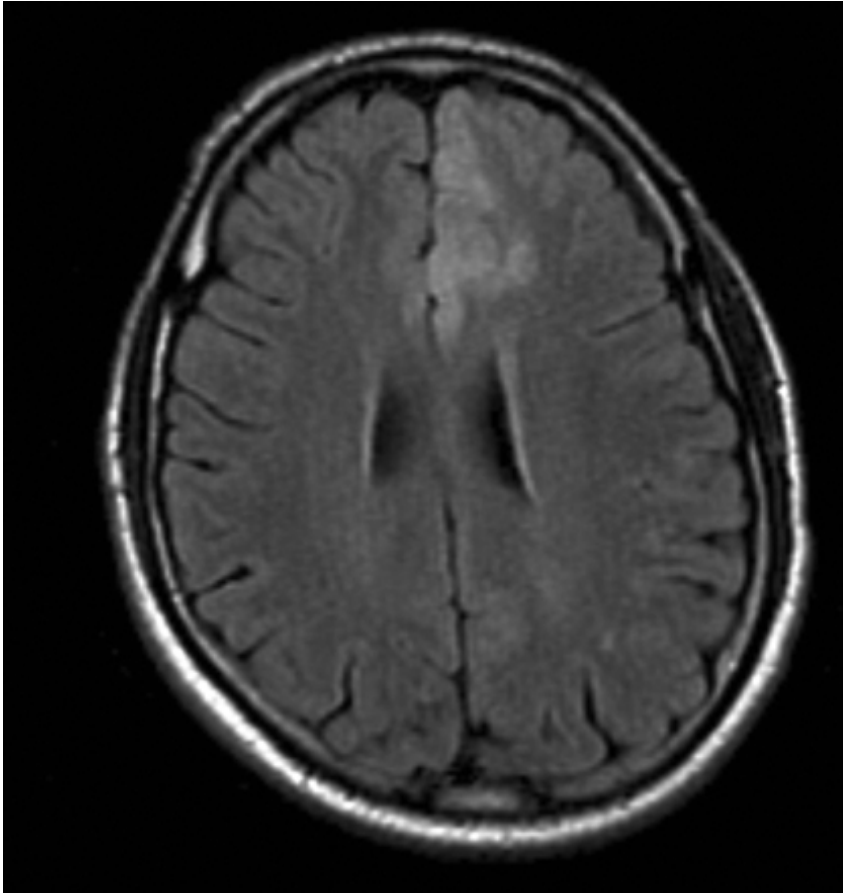


Ki67

**Astrocitoma
subependimario
de células gigantes
(grado I de la OMS 2007)**

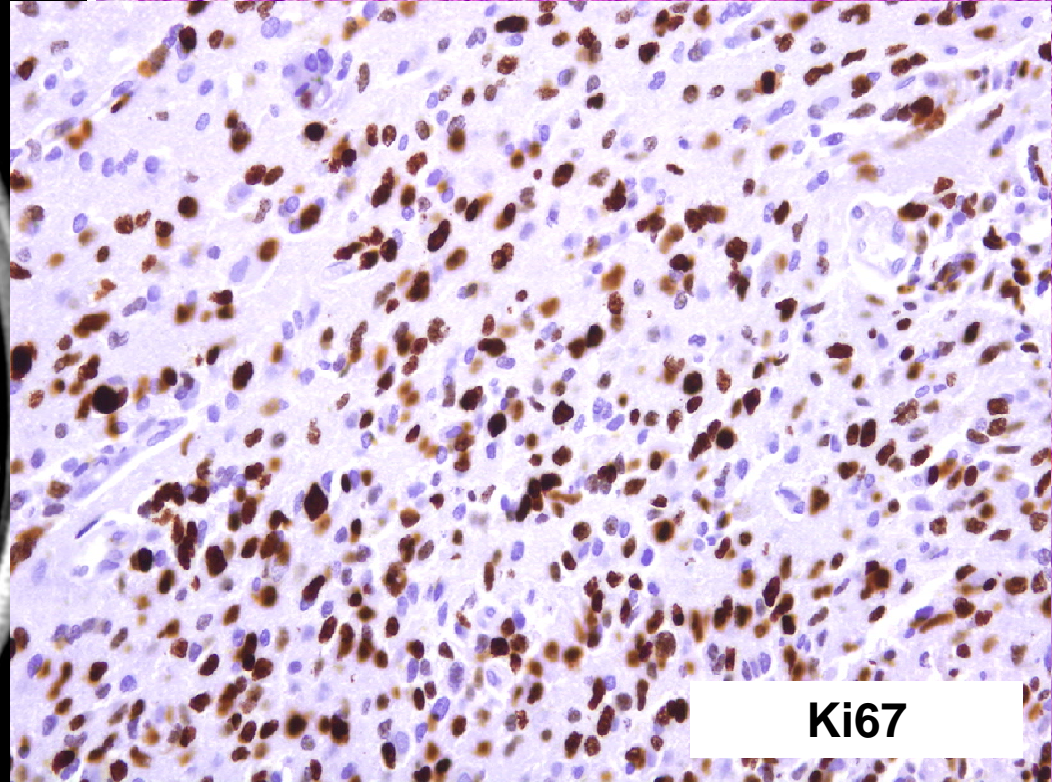
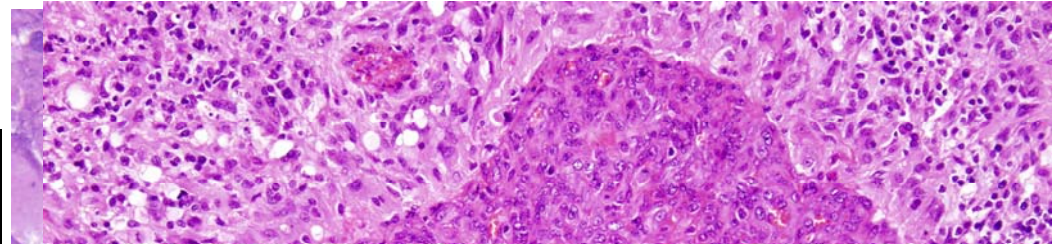
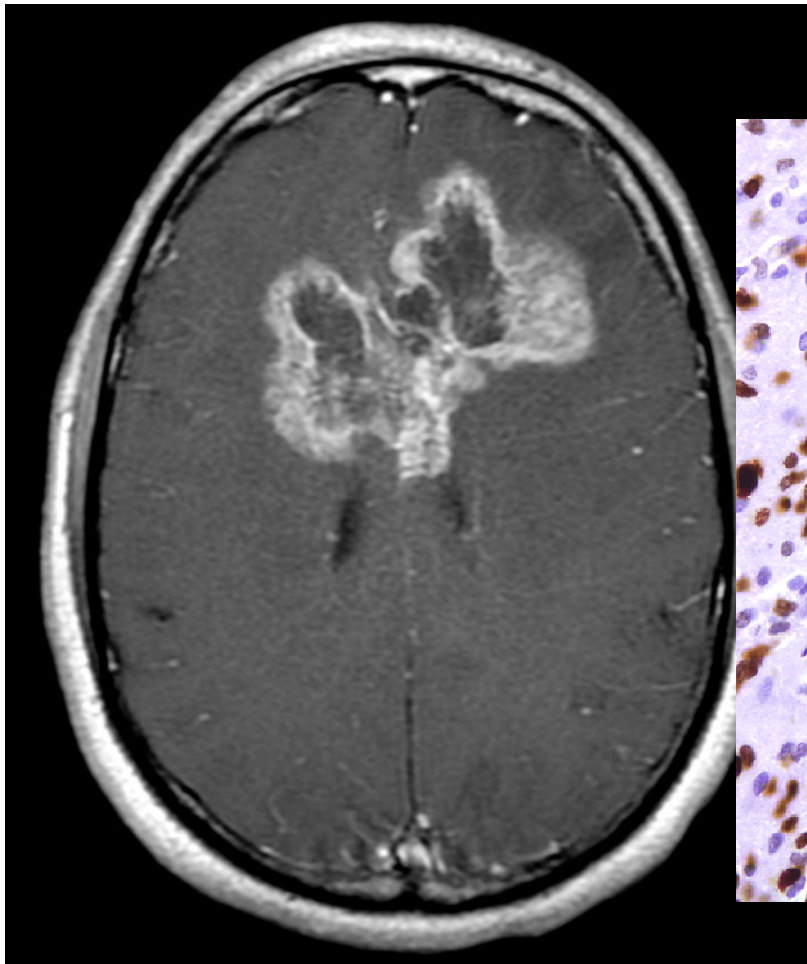
ASCG: Diagnóstico diferencial

Astrocitoma gemistocítico



ASCG: Diagnóstico diferencial

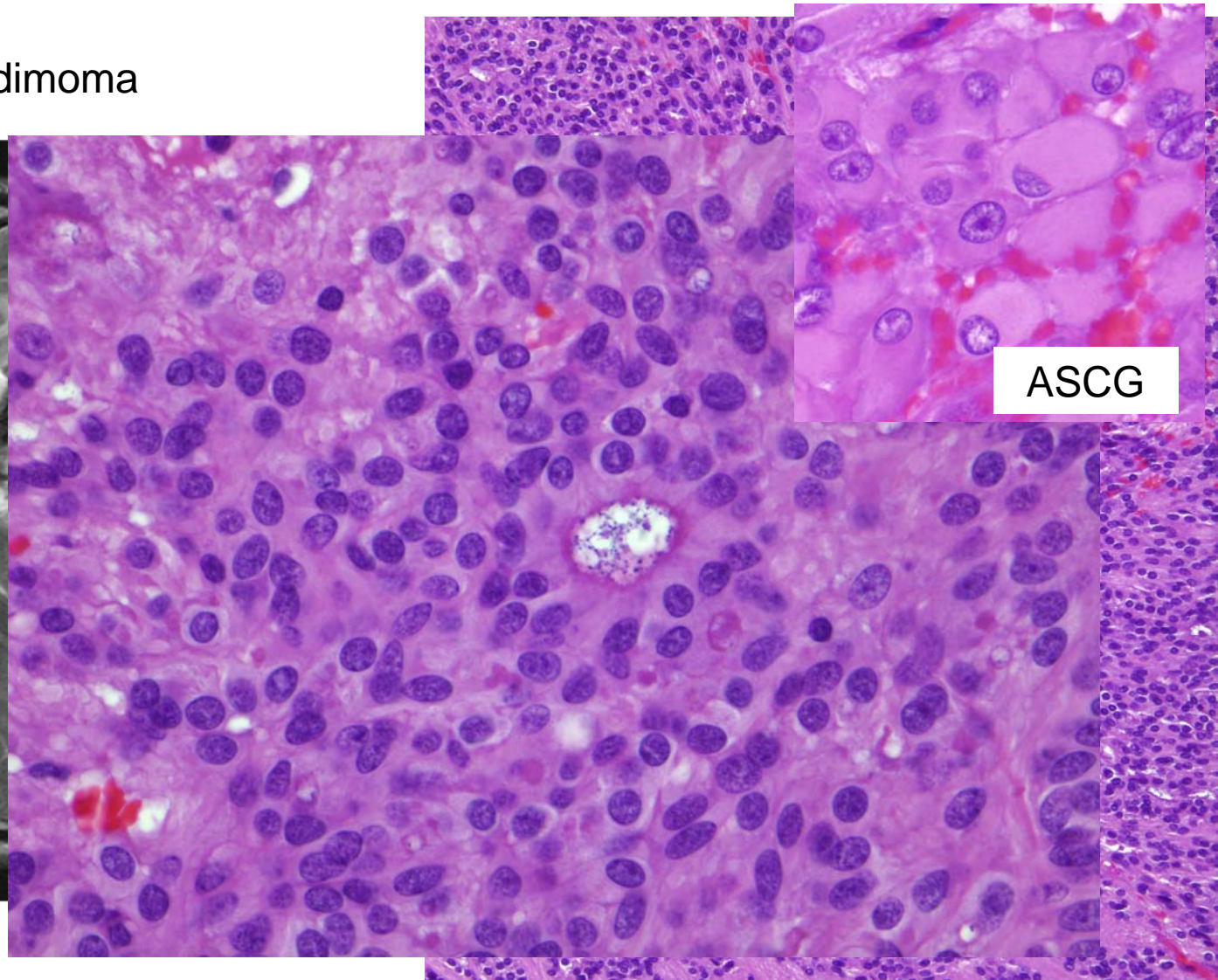
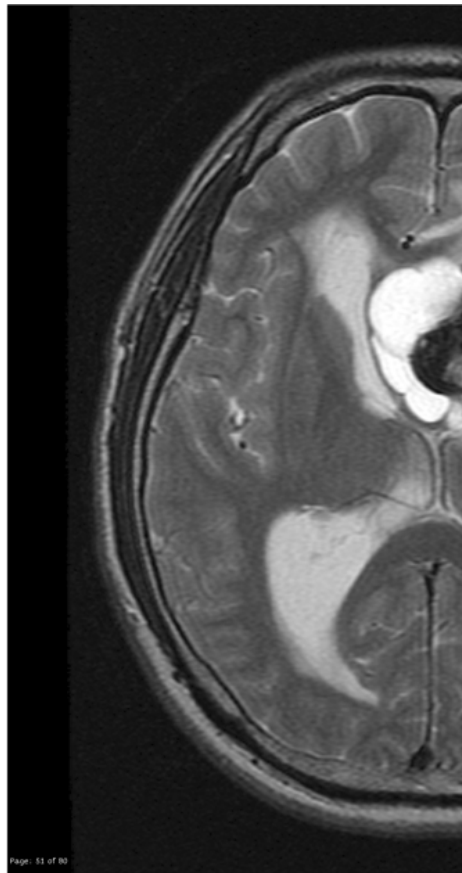
Glioblastoma



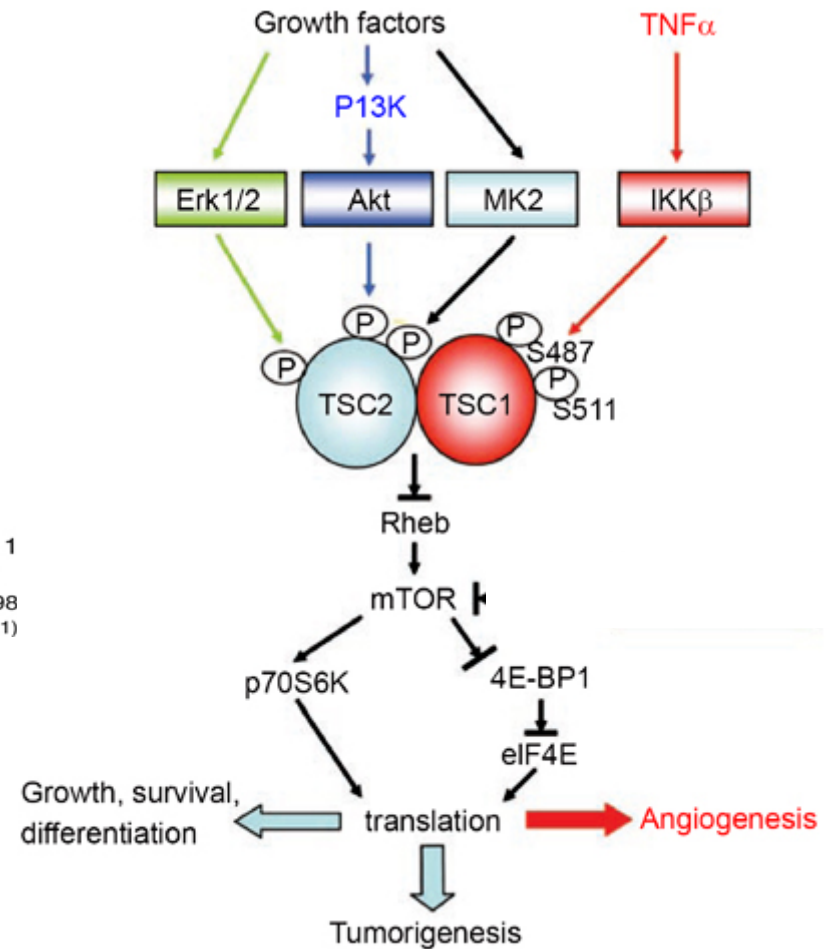
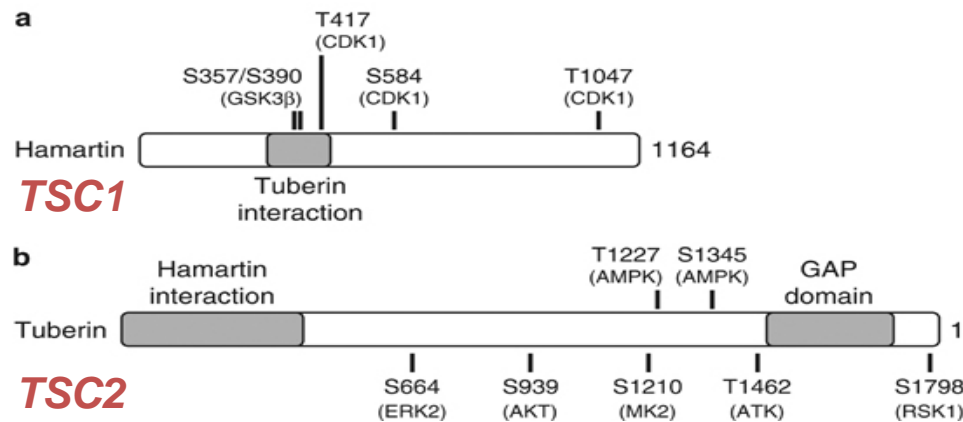
Ki67

ASCG: Diagnóstico diferencial

Ependimoma



ASCG: *Esclerosis Tuberosa*



ASCG: *Esclerosis Tuberosa*

Major features	Minor features
<u>Facial angifibromas or forehead plaque</u>	Multiple, randomly distributed pits in dental enamel
Nontraumatic unguual or periungual fibroma	Hamartomatous rectal polyps
<u>Hypomelanotic macule (3 or more)</u>	Bone cysts: radiographic confirmation is sufficient
Shagreen patch (connective tissue nevus)	Cerebral white matter radial migration lines
Multiple retinal nodular hamartomas	Gingival fibromas
<u>Cortical tubers</u>	<u>Nonrenal hamartomas</u>
<u>Subependymal nodule</u>	Retinal achromic patch
<u>Subependymal giant cell astrocytoma</u>	“Confetti” skin lesions
Cardiac rhabdomyoma, single or multiple	Multiple renal cysts
Lymphangiomyomatosis: when both lymphangiomyomatosis (LAM) and renal angiomyolipomas (AMLs) are present, other features of tuberous sclerosis should be present before a definite diagnosis is assigned	
<u>Renal angiomyolipoma</u> : when both LAM and renal AMLs are present, other features of tuberous sclerosis should be present before a definite diagnosis is assigned (see previous remarks)	

Folia Neuropathol 2010;48 (3): 139-49.

- 6-14% de los pacientes con Esclerosis Tuberosa padecen ASCG

ASCG: Tratamiento

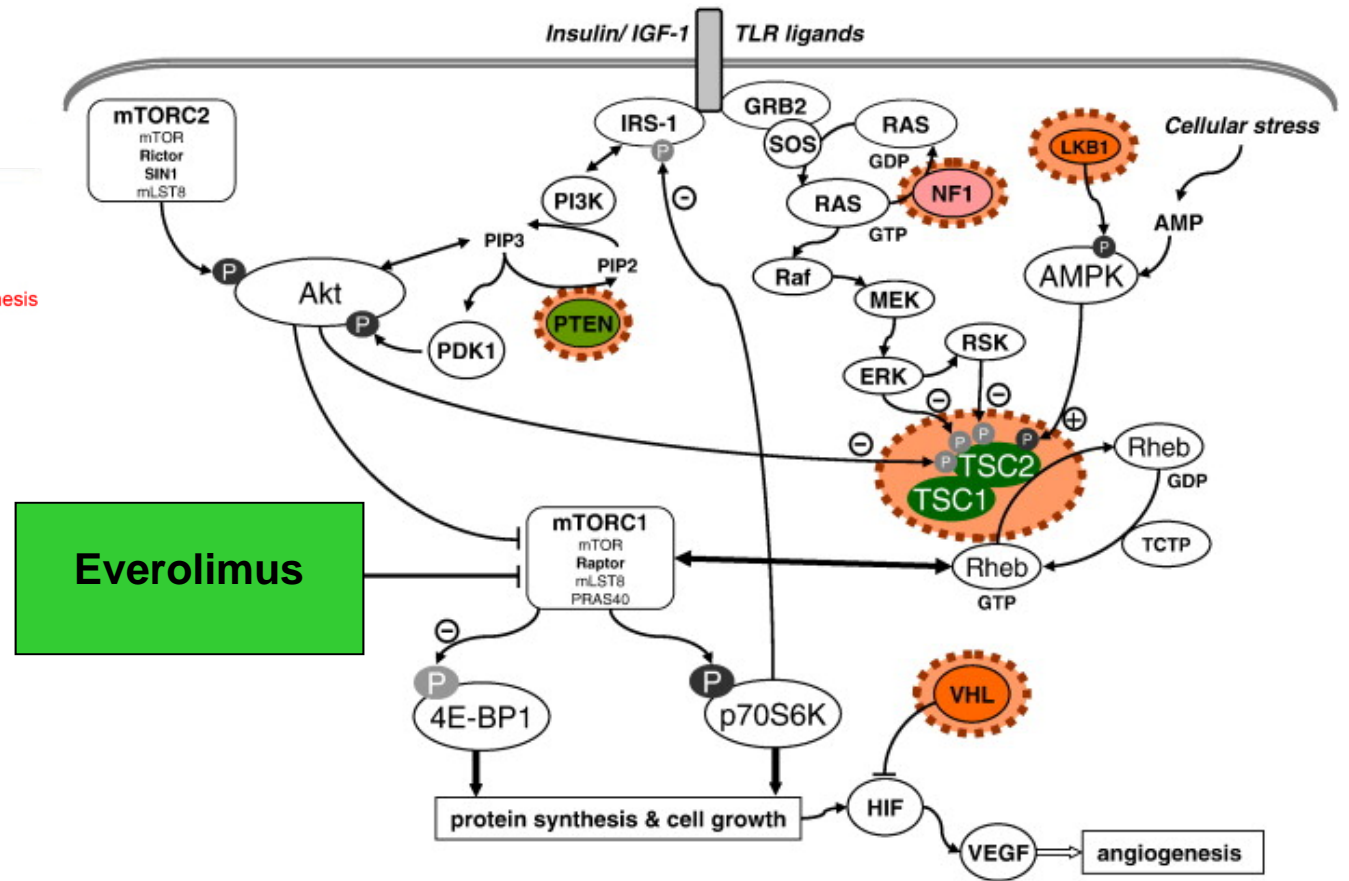
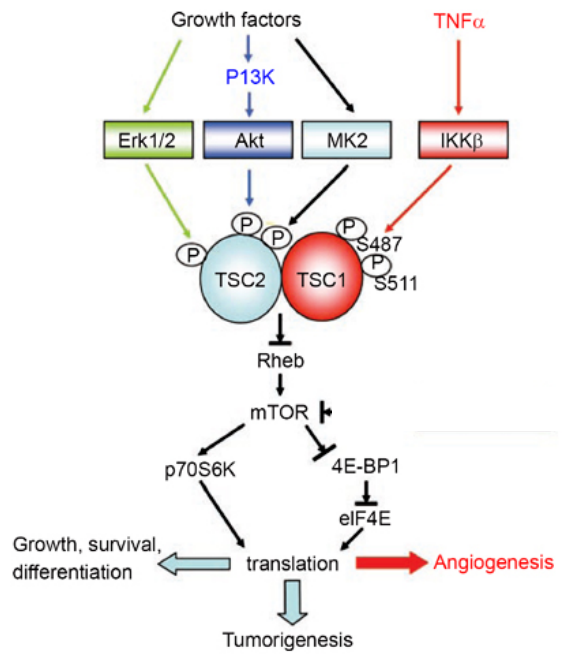
The NEW ENGLAND JOURNAL of MEDICINE

ORIGINAL ARTICLE

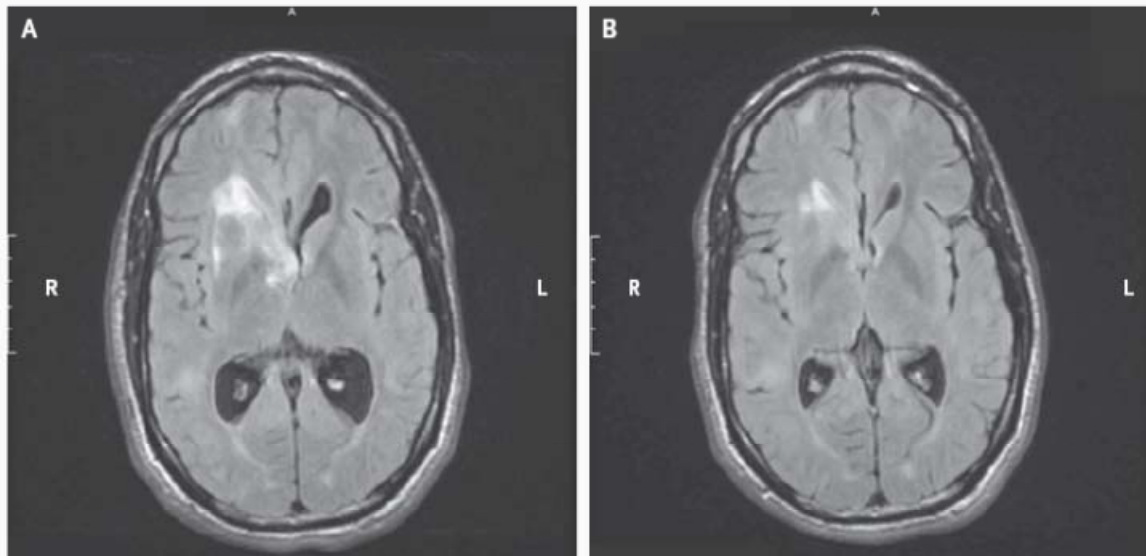
Everolimus for Subependymal Giant-Cell Astrocytomas in Tuberous Sclerosis

Darcy A. Krueger, M.D., Ph.D., Marguerite M. Care, M.D.,
Katherine Holland, M.D., Ph.D., Karen Agricola, F.N.P., Cynthia Tudor, P.N.P.,
Prajakta Mangeshkar, M.S., Kimberly A. Wilson, M.S., Anna Byars, Ph.D.,
Tarek Sahmoud, M.D., Ph.D., and David Neal Franz, M.D.

N Engl J Med. 2010; 363 (19): 1801-11

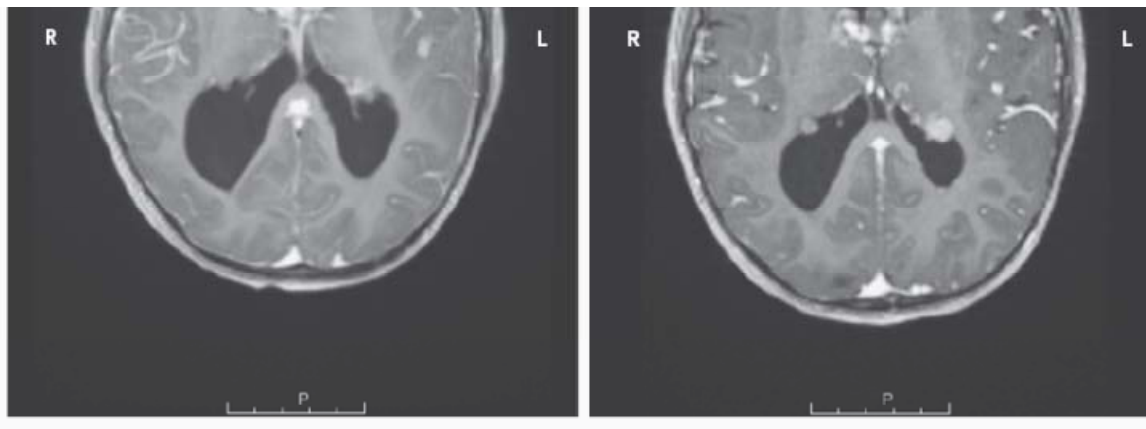


Everolimus



CONCLUSIONS

Everolimus therapy was associated with marked reduction in the volume of subependymal giant-cell astrocytomas and seizure frequency and may be a potential alternative to neurosurgical resection in some cases, though long-term studies are needed. (Funded by Novartis; ClinicalTrials.gov number, NCT00411619.)



Expert Opinion

1. Tuberous sclerosis
2. Sirolimus

Everolimus tablets for patients with subependymal giant cell astrocytoma

Scott G Turner, Katherine B Peters, James J Vredenburgh, Annick Desjardins, Henry S Friedman & David A Reardon[†]

Expert Opin. Pharmacother. (2011) **12**(14)

www.impactaging.com

AGING, March 2011, Vol. 3, No. 3

Commentaries & Editorials

Potential of mTOR inhibitors for the treatment of subependymal giant cell astrocytomas in tuberous sclerosis complex

Philippe Major

Department of Pediatrics, Neurology Service, Centre Hospitalier Universitaire Sainte-Justine, Université de Montréal, Montréal, Québec, Canada

Case study

EUROPEAN JOURNAL OF PAEDIATRIC NEUROLOGY 16 (2012) 83–85

Effective everolimus treatment of inoperable, life-threatening subependymal giant cell astrocytoma and intractable epilepsy in a patient with tuberous sclerosis complex

Marta Perek-Polnik^a, Sergiusz Józwiak^b, Elżbieta Jurkiewicz^c, Danuta Perek^a, Katarzyna Kotulska^{b,d,*}

Everolimus: Tratamiento

- Usos autorizados por la FDA
 - Tratamiento del cáncer renal
 - Profilaxis del rechazo de transplantes
 - Tratamiento del SEGAs en pacientes no candidatos a cirugía
- Ensayos en fase III
 - Tratamiento de SEGAs (NCT00789828)
 - Tratamiento de cáncer de mama, gástrico, carcinoma hepatocelular, tumores pancreáticos neuroendocrinos, linfomas.

Everolimus: Tratamiento

- Ensayos en fase III
 - Tratamiento de los angiomiolipomas en TSC y de los linfangioleiomiomatosis esporádica (NCT00790400)
- Ensayos en fase II
 - Glioma de bajo grado recurrente o progresivo en adultos (NCT00831324)
 - Glioblastoma en tratamiento combinado en primera línea con quimioradioterapia con temozolomida (NCT00553150)

**Astrocitoma
subependimario
de células gigantes
(grado I de la OMS 2007)**