

SOCIETAT
CATALANA
DE CITO
PATOLOGIA




Seminari de casos de patologia pediàtrica, amb correlació C/H

Rovira C, Marginet M

Hospital Sant Joan de Déu, Barcelona

SOCIETAT CATALANA



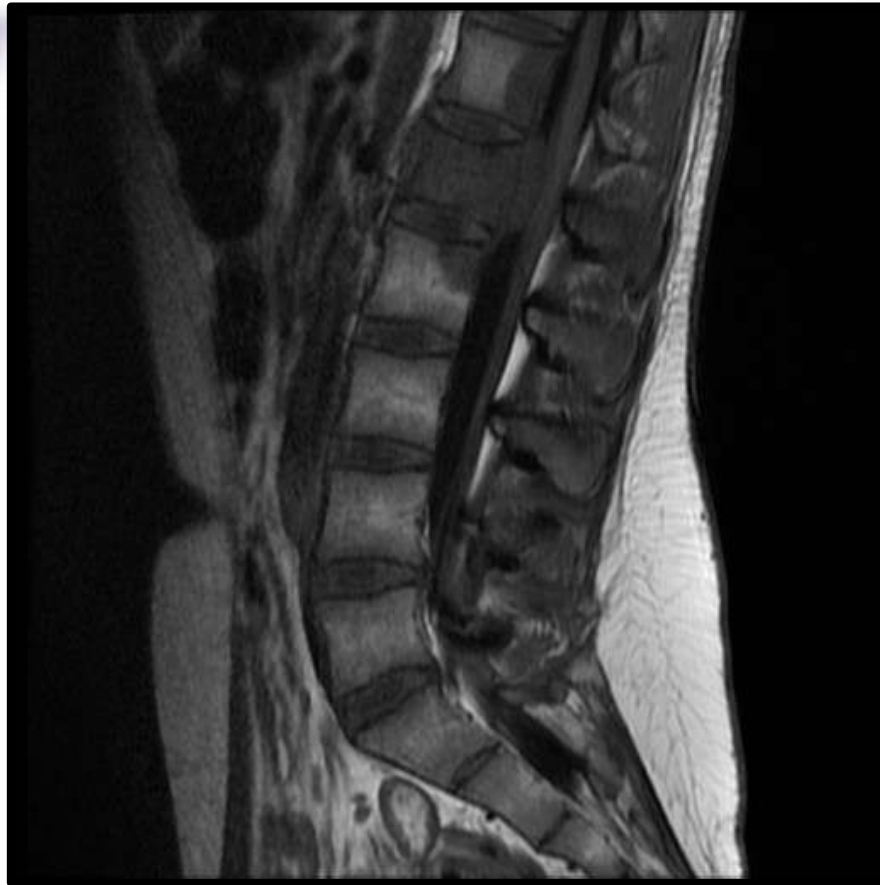D'ANATOMIA PATOLÒGICA



HISTÒRIA CLÍNICA

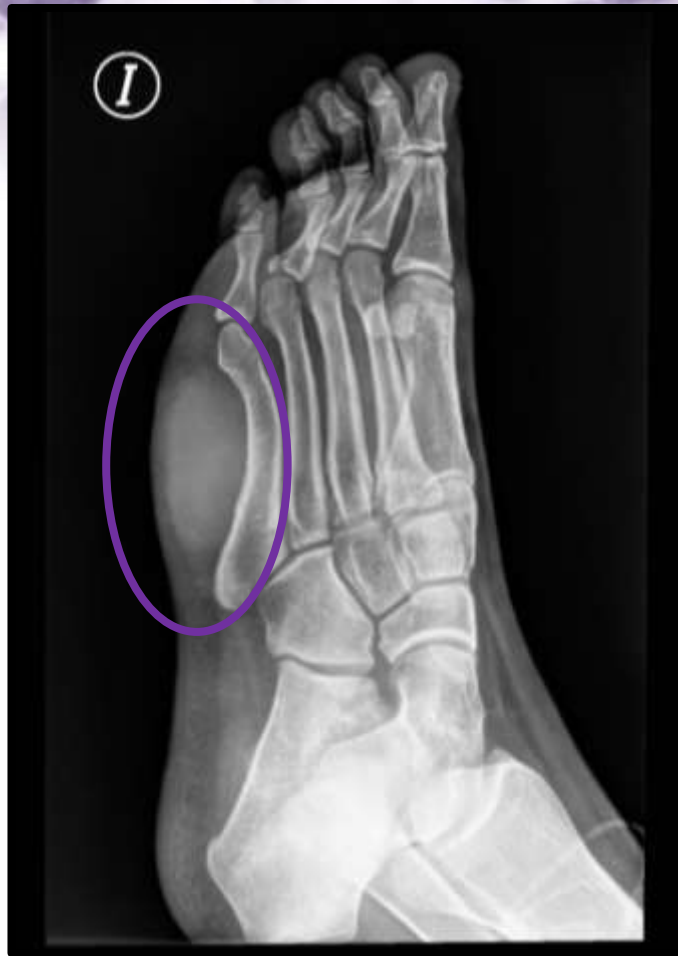- Noi de 14 a
- Dolor d'esquena
- No antecedents patològics d'interès

RADIOLOGIA



RM imatges lítiques vertebrals múltiples

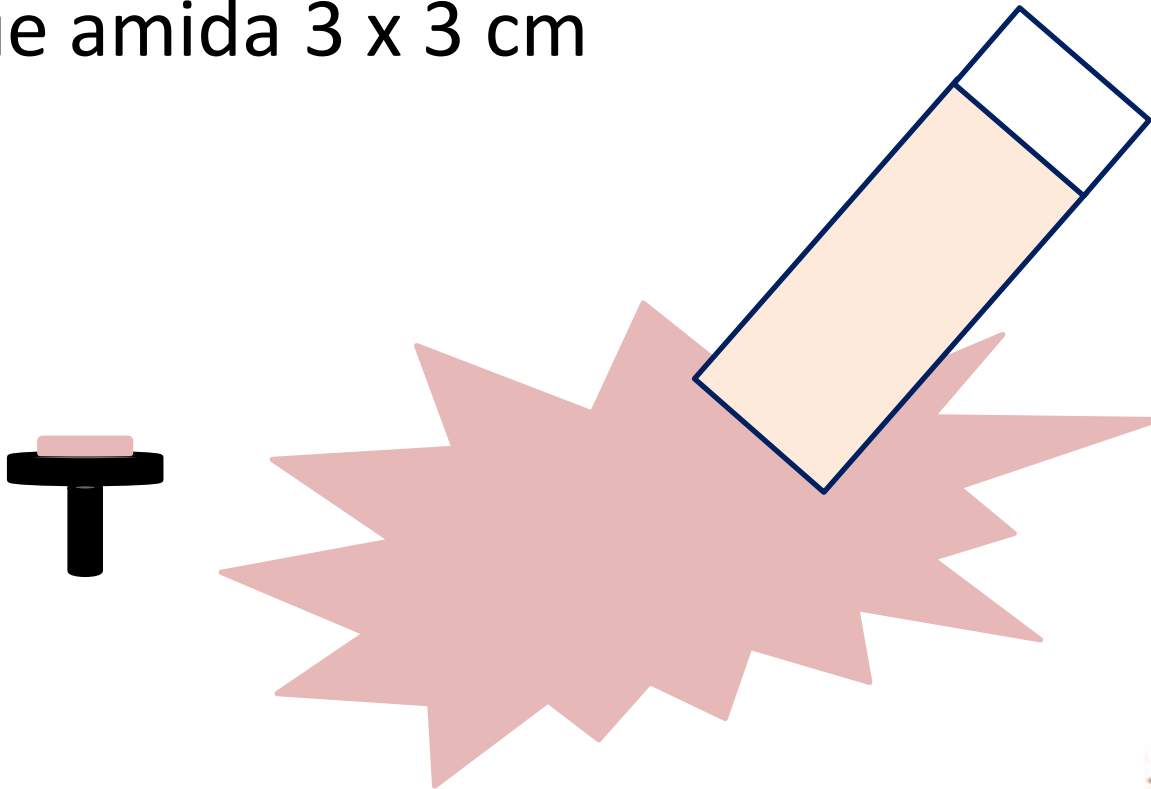
RADIOLOGIA



Tumoració de parts toves al dors extern del peu esquerre

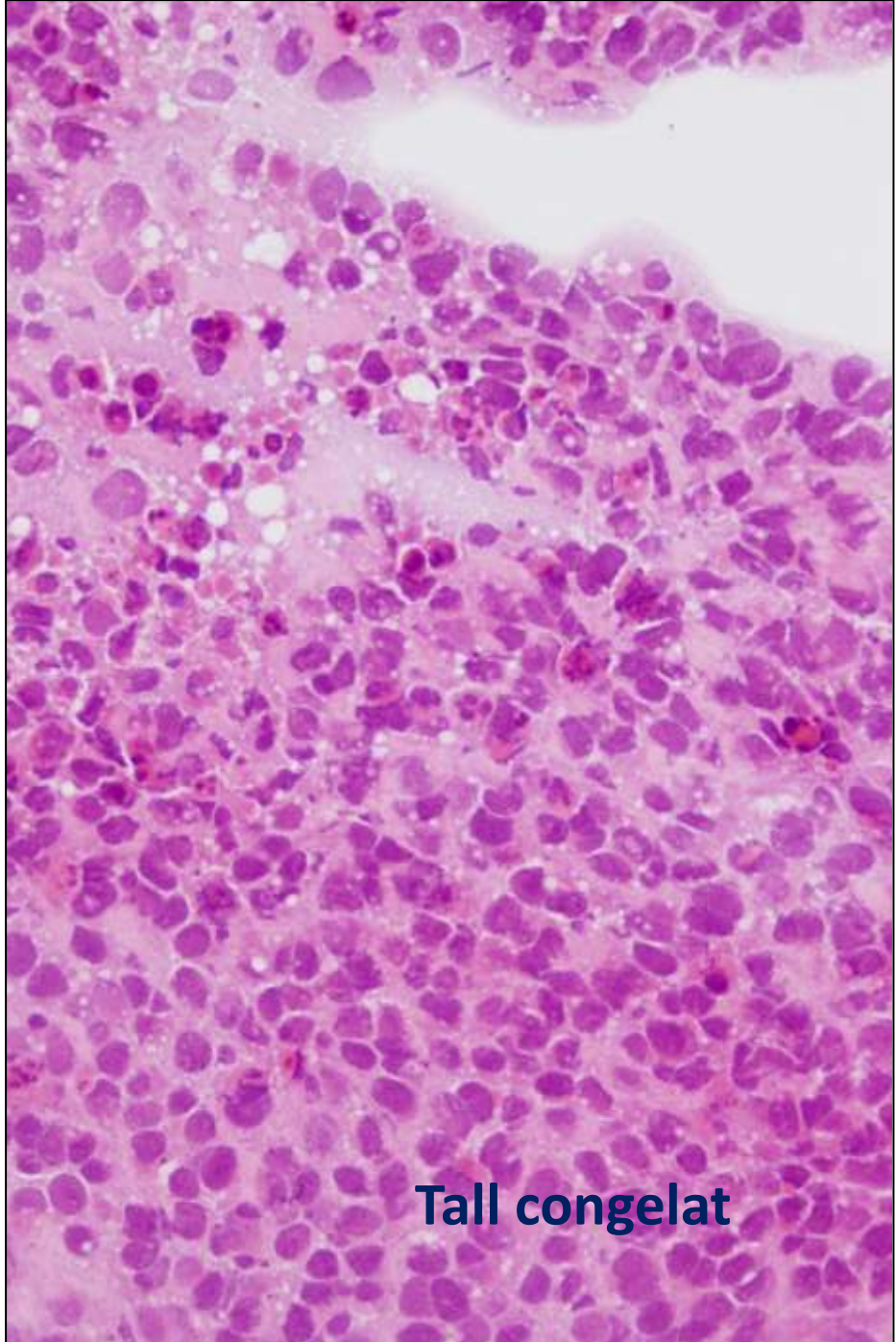
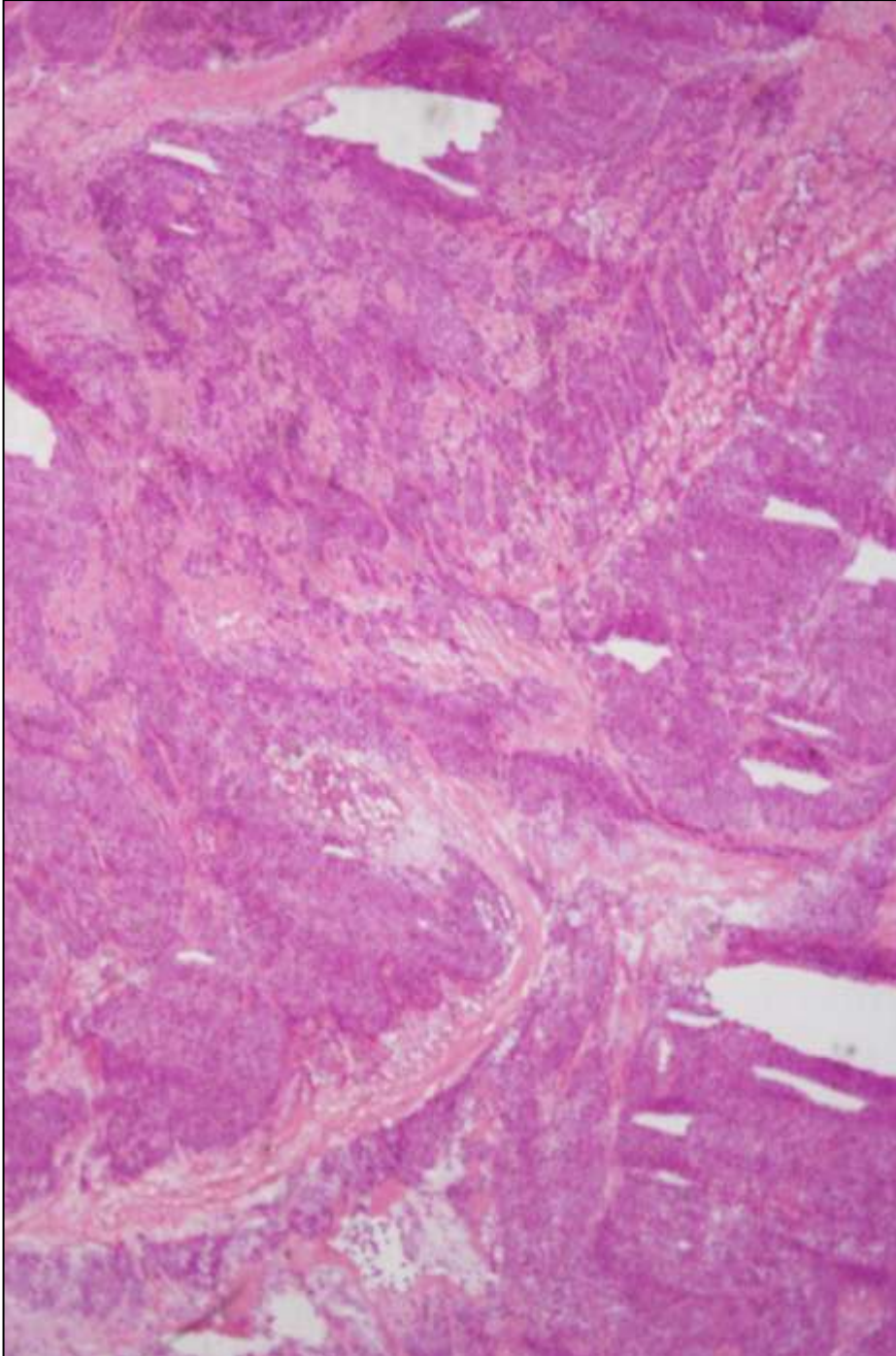
MACROSCOPIA

Fragment de teixit elàstic, d'aspecte gelatinós
que amida 3 x 3 cm

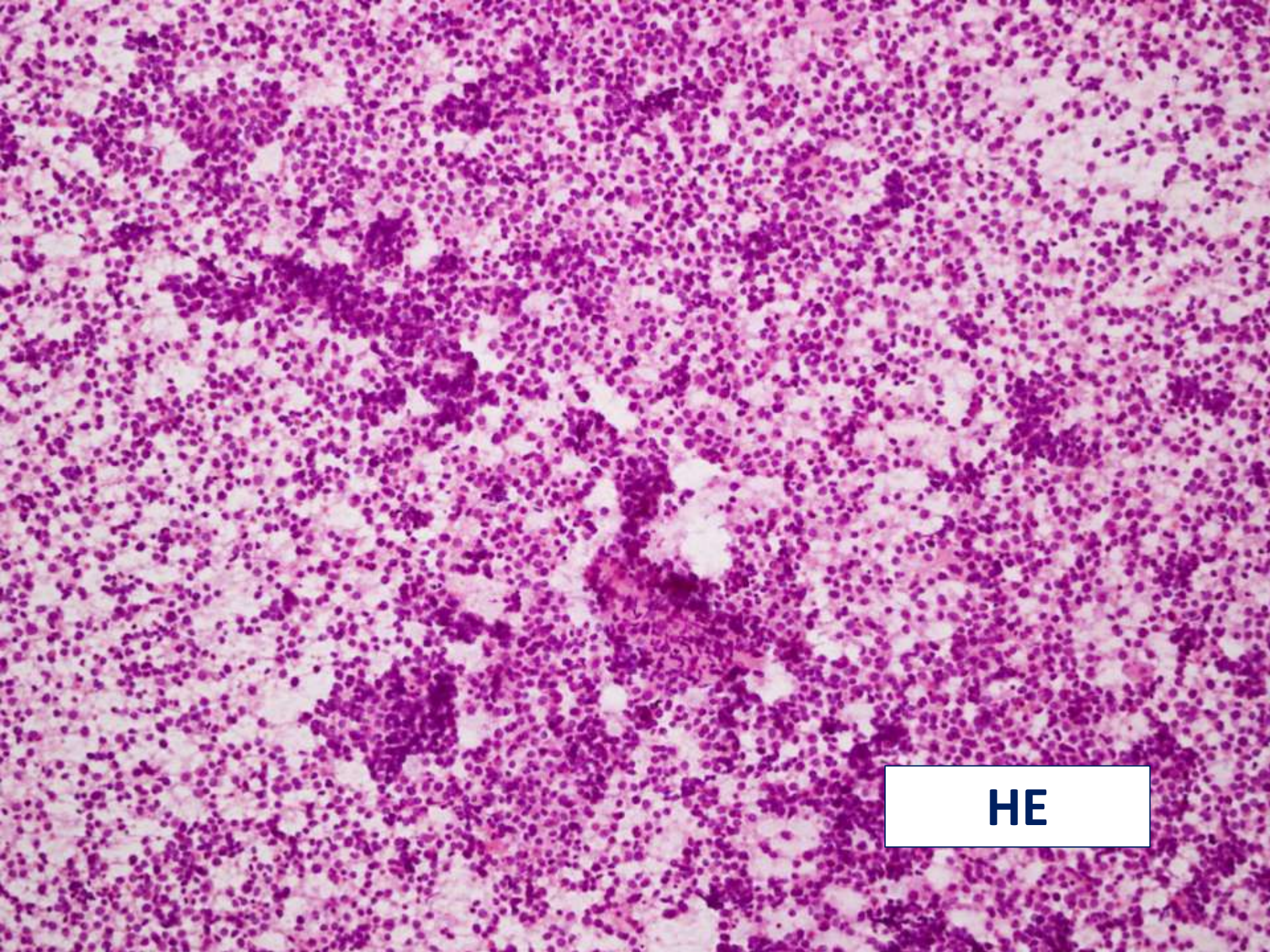


OBJECTIUS

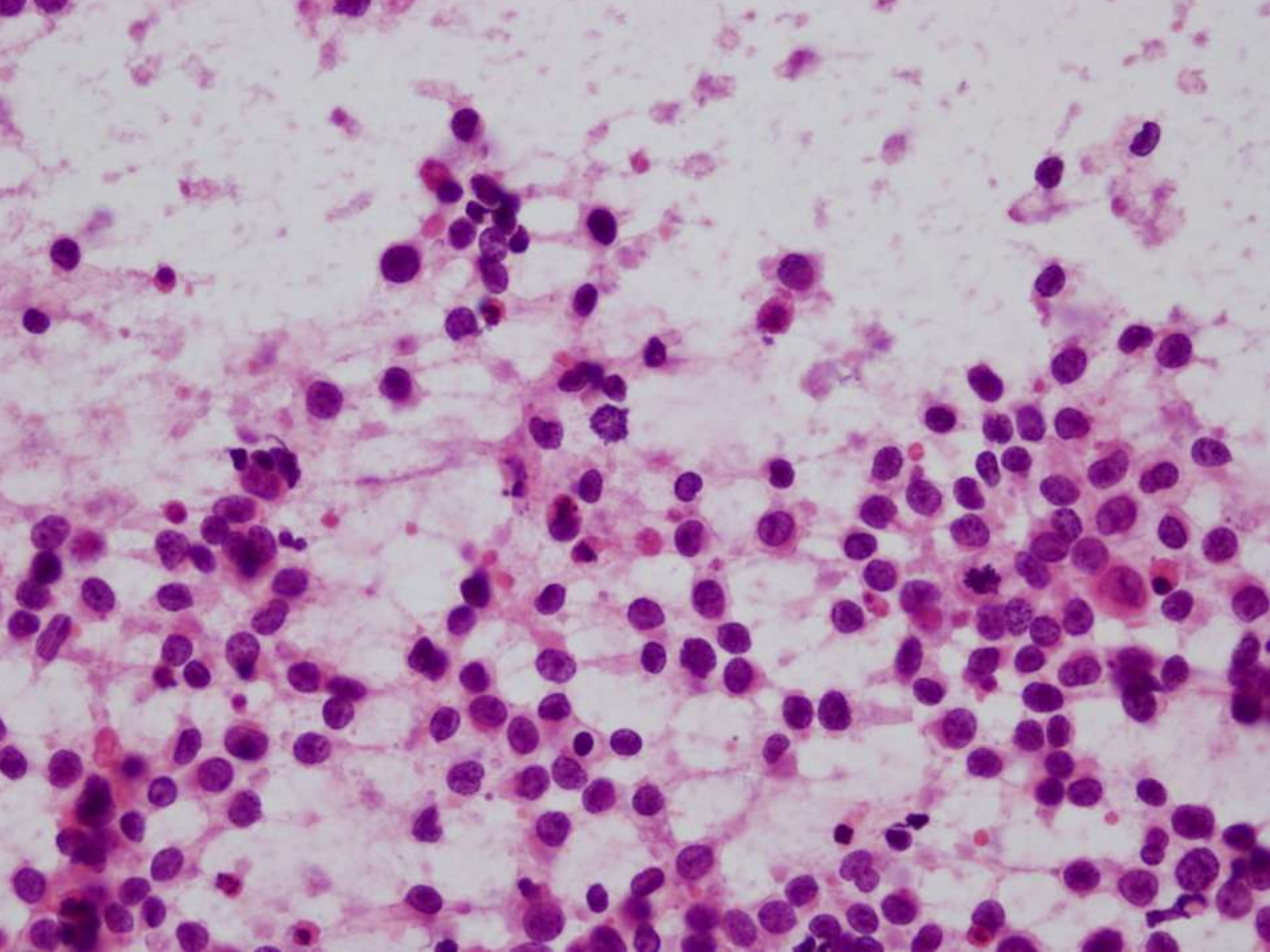
- Material representatiu de lesió tumoral
- Benigne/Maligne
- Viabilitat de les cèl·lules tumorals : estudis moleculars
- Orientar diagnòstic més probable: prioritzar l'estudi

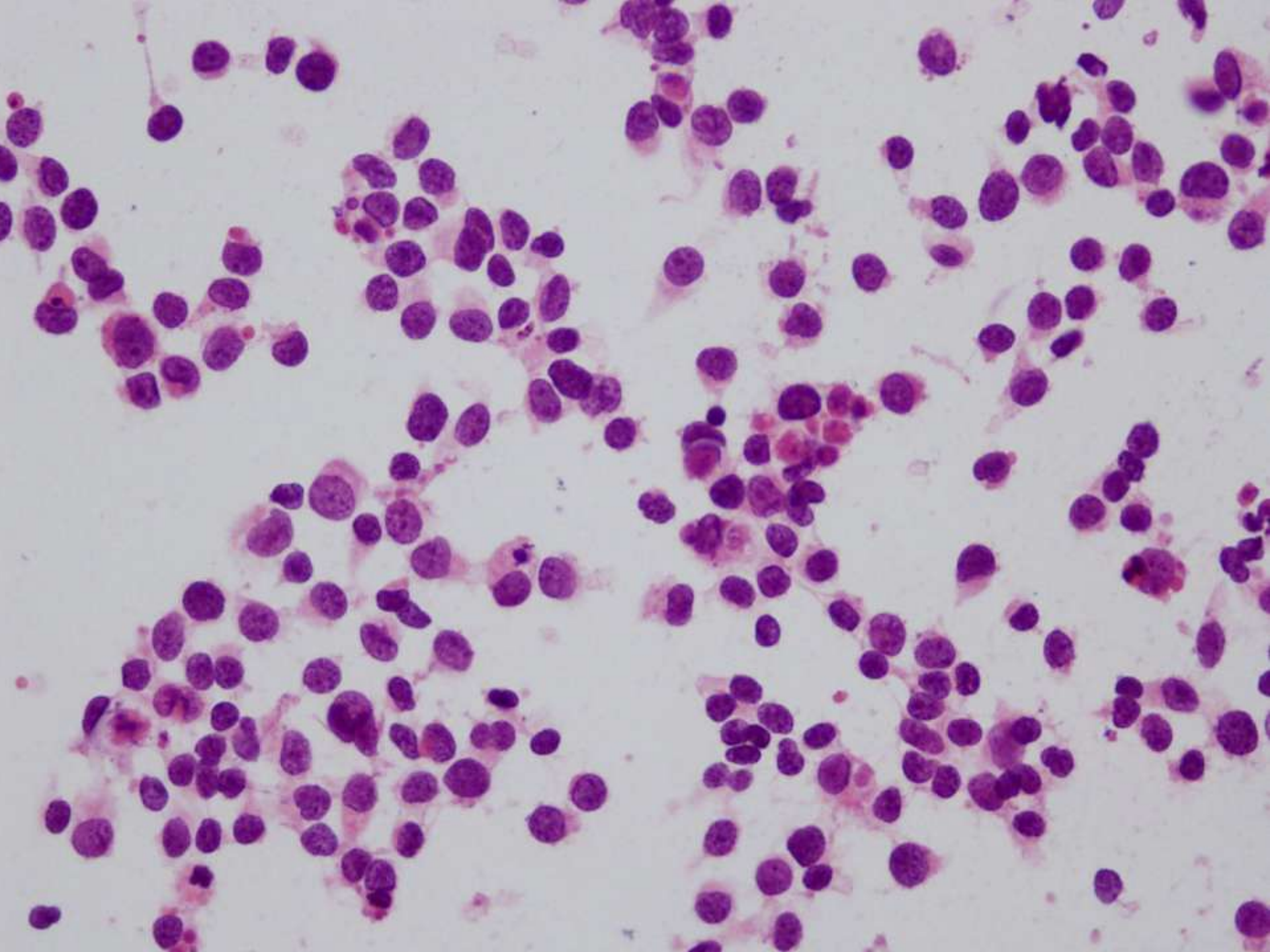


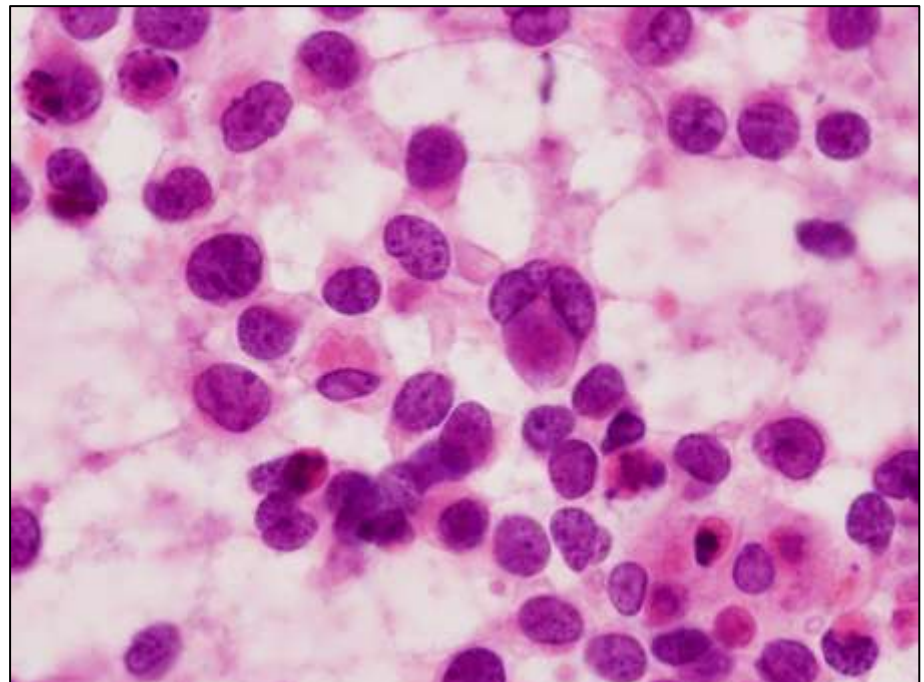
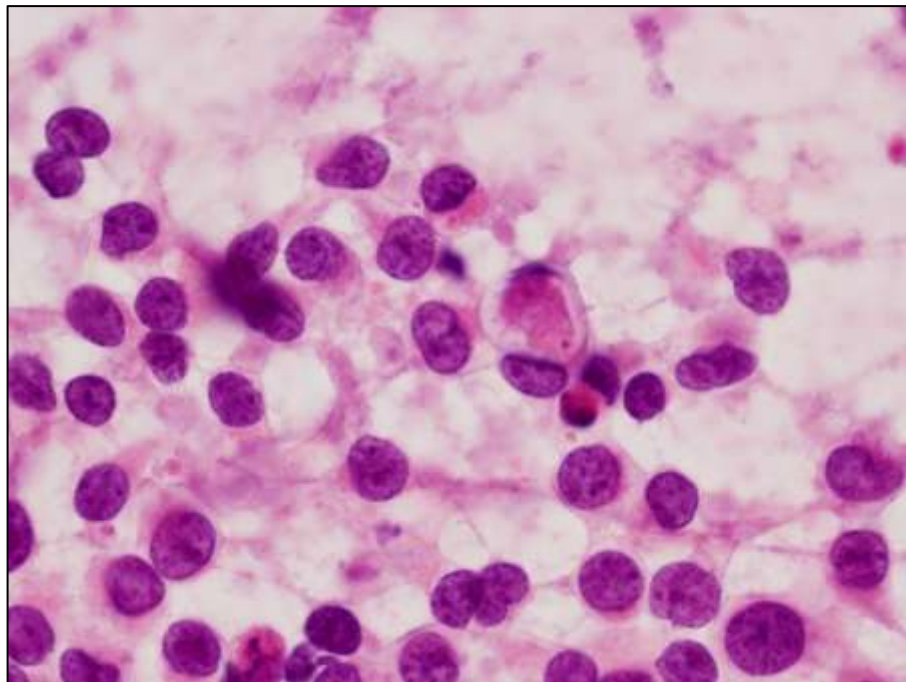
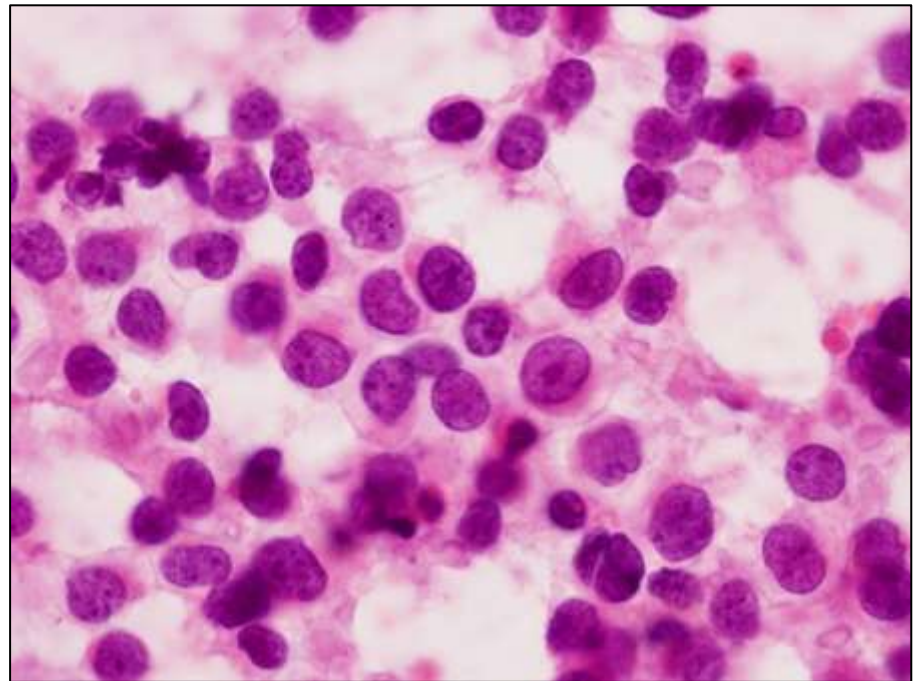
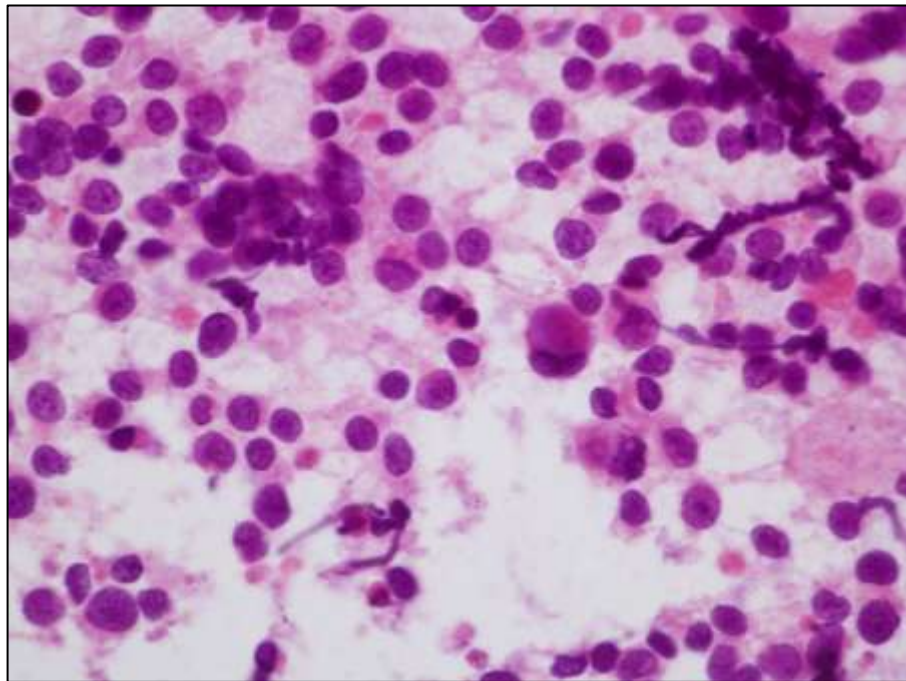
Tall congelat



HE

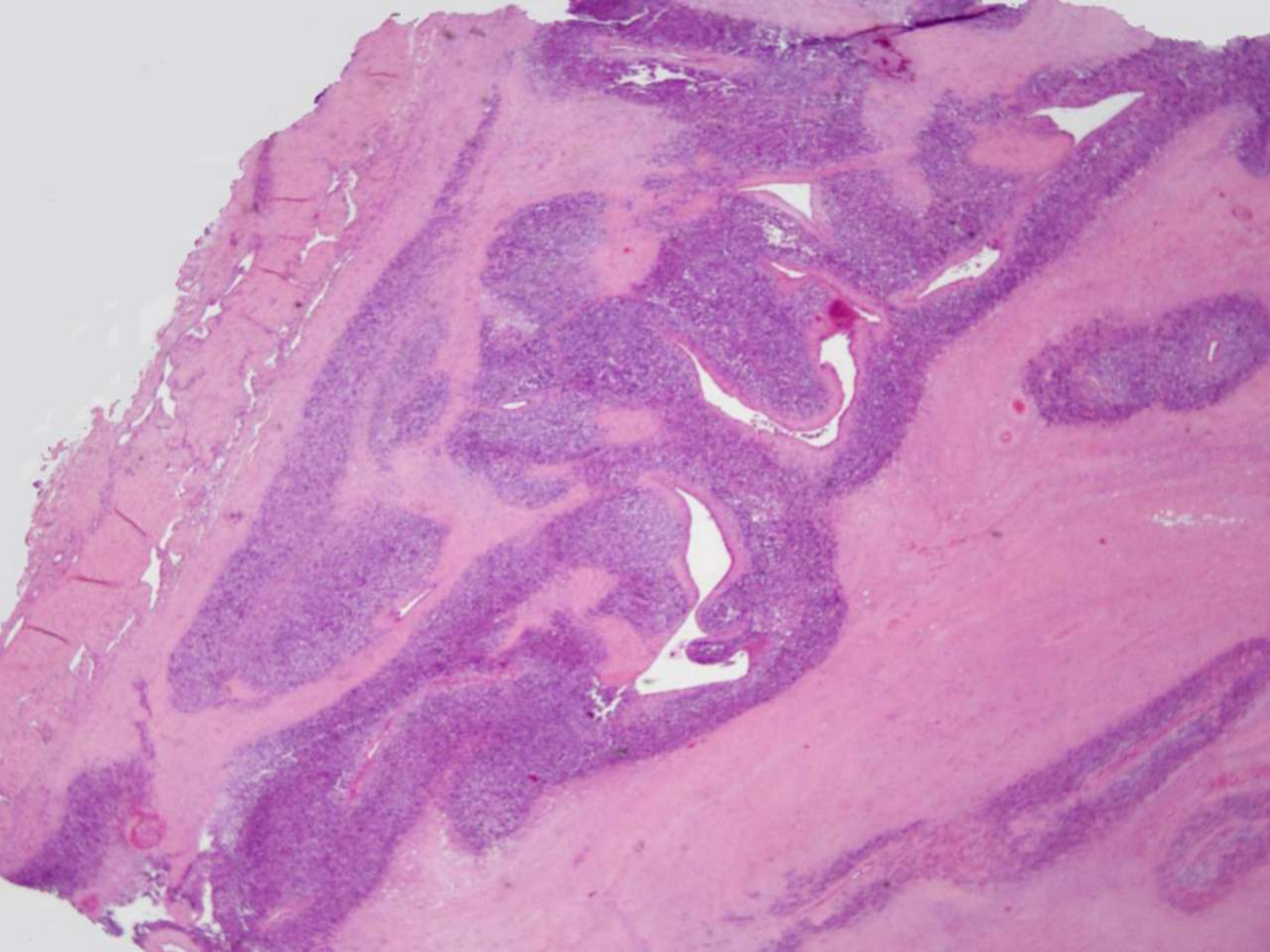


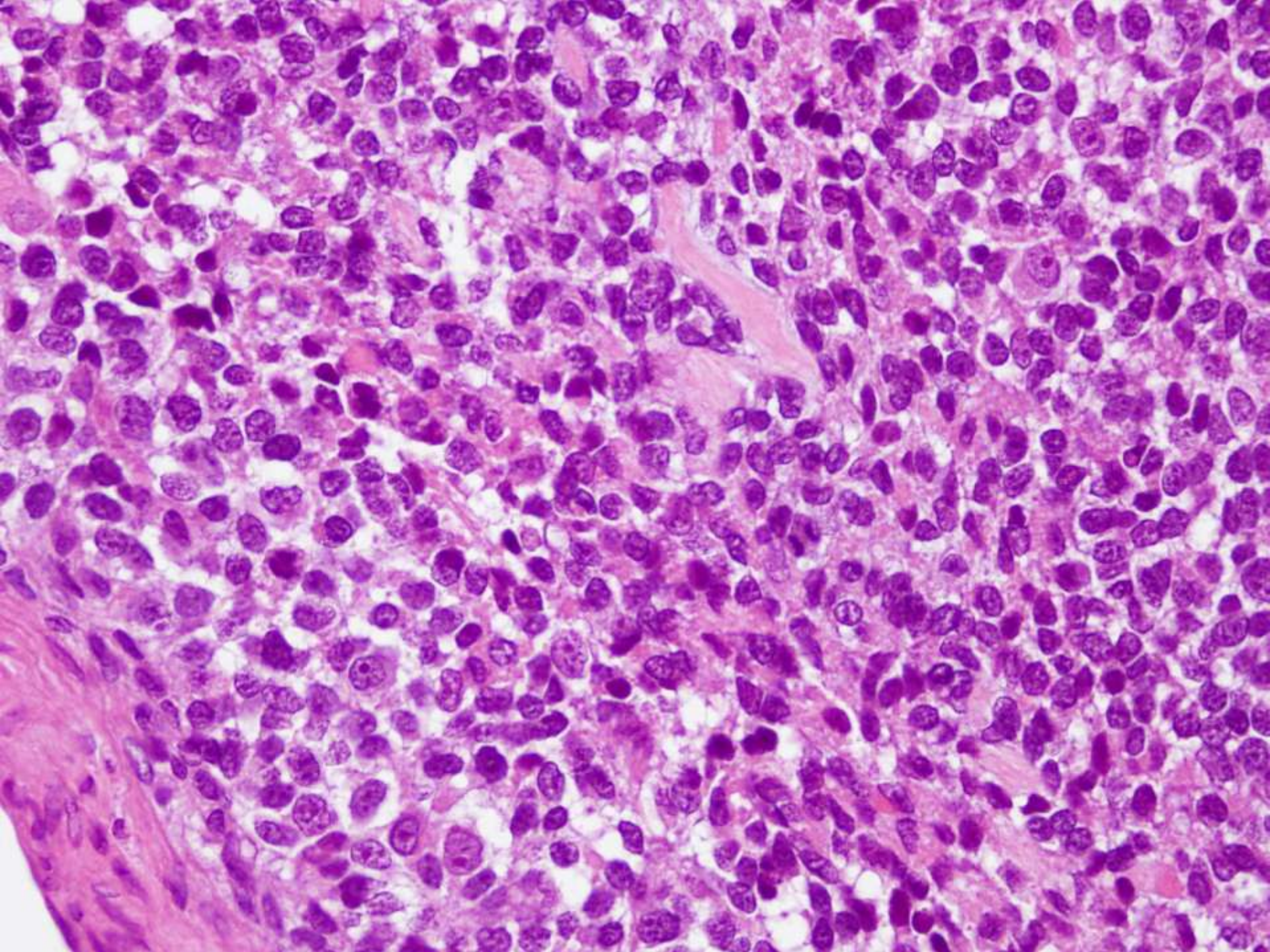


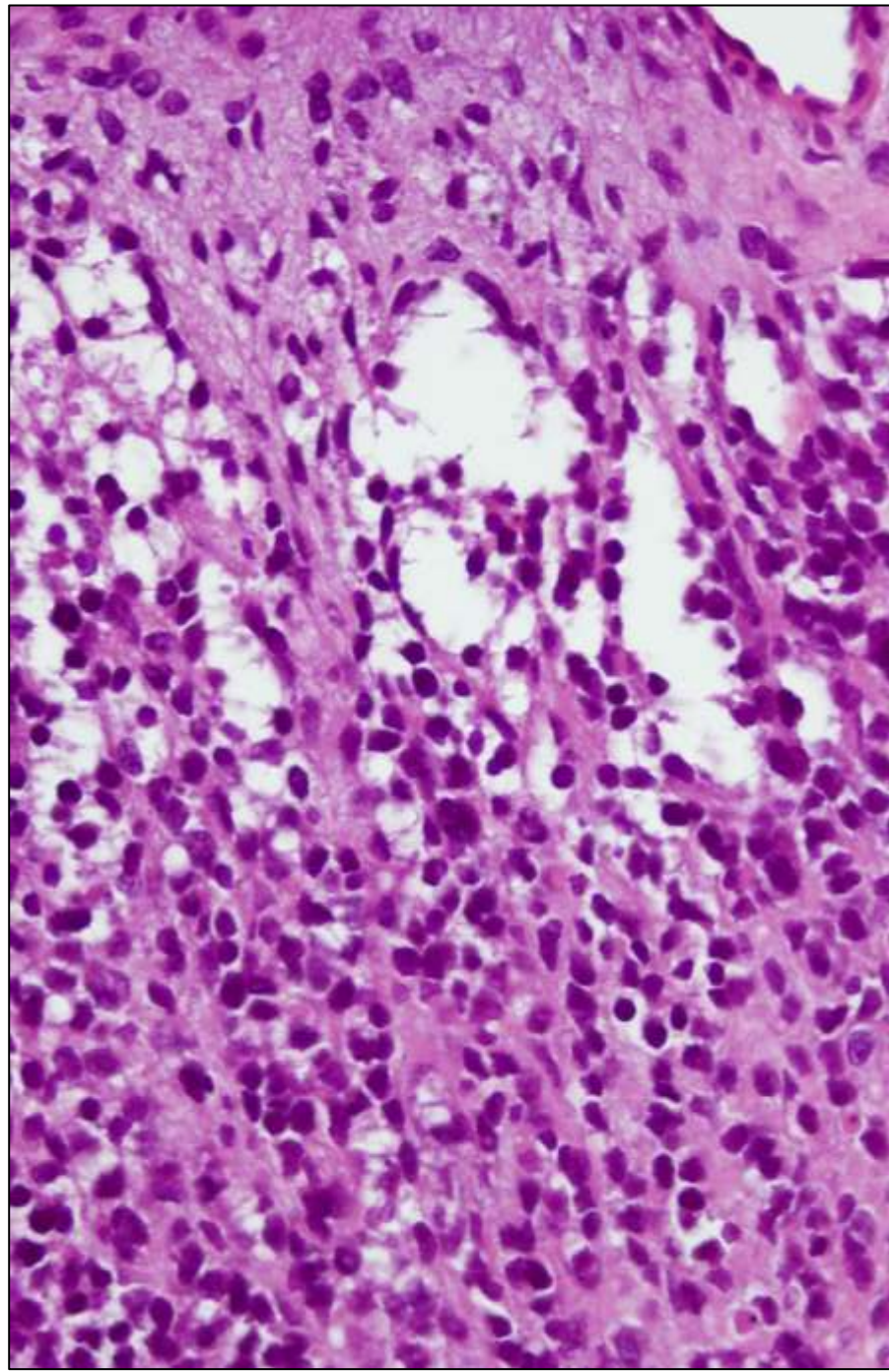
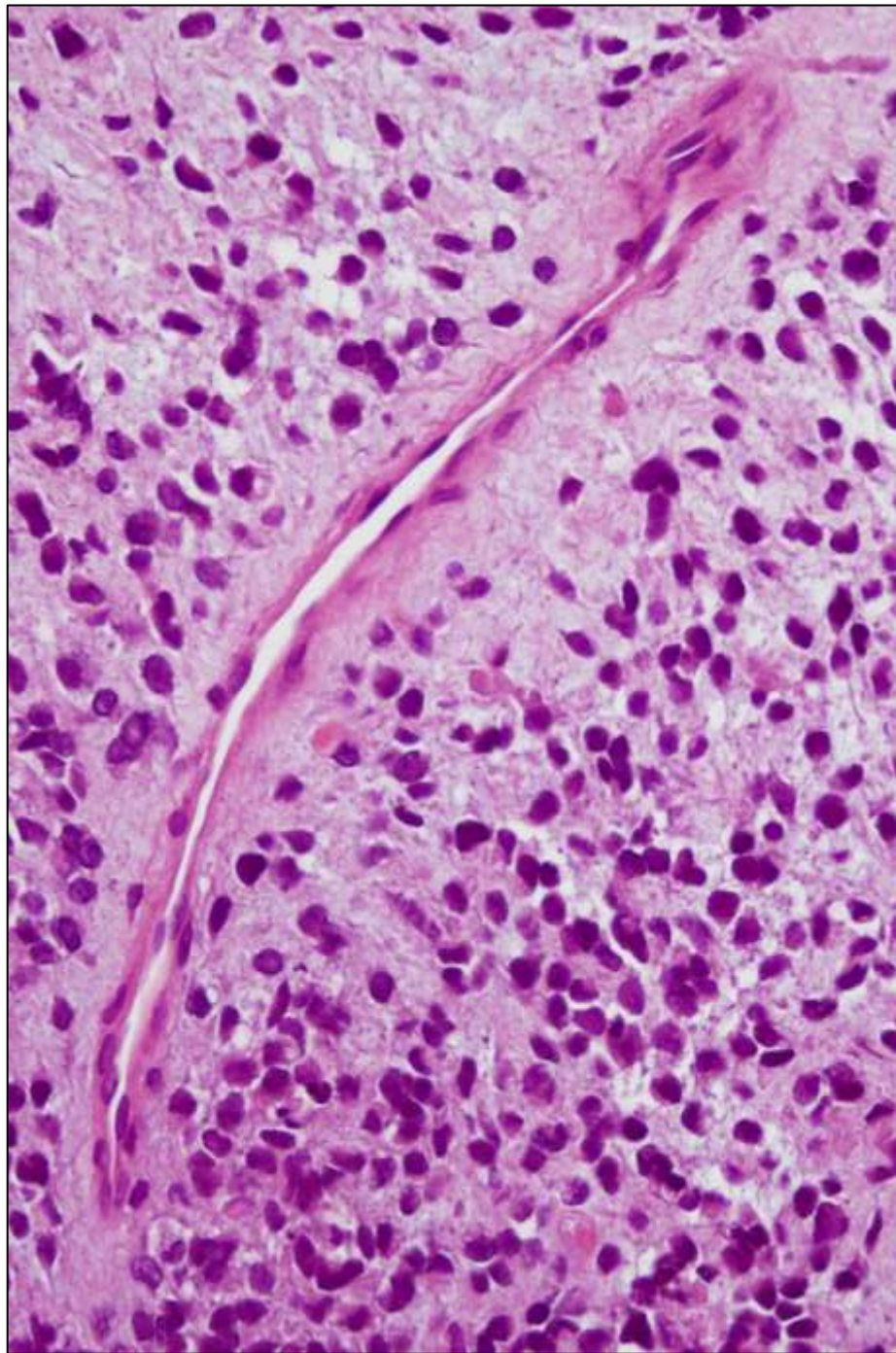


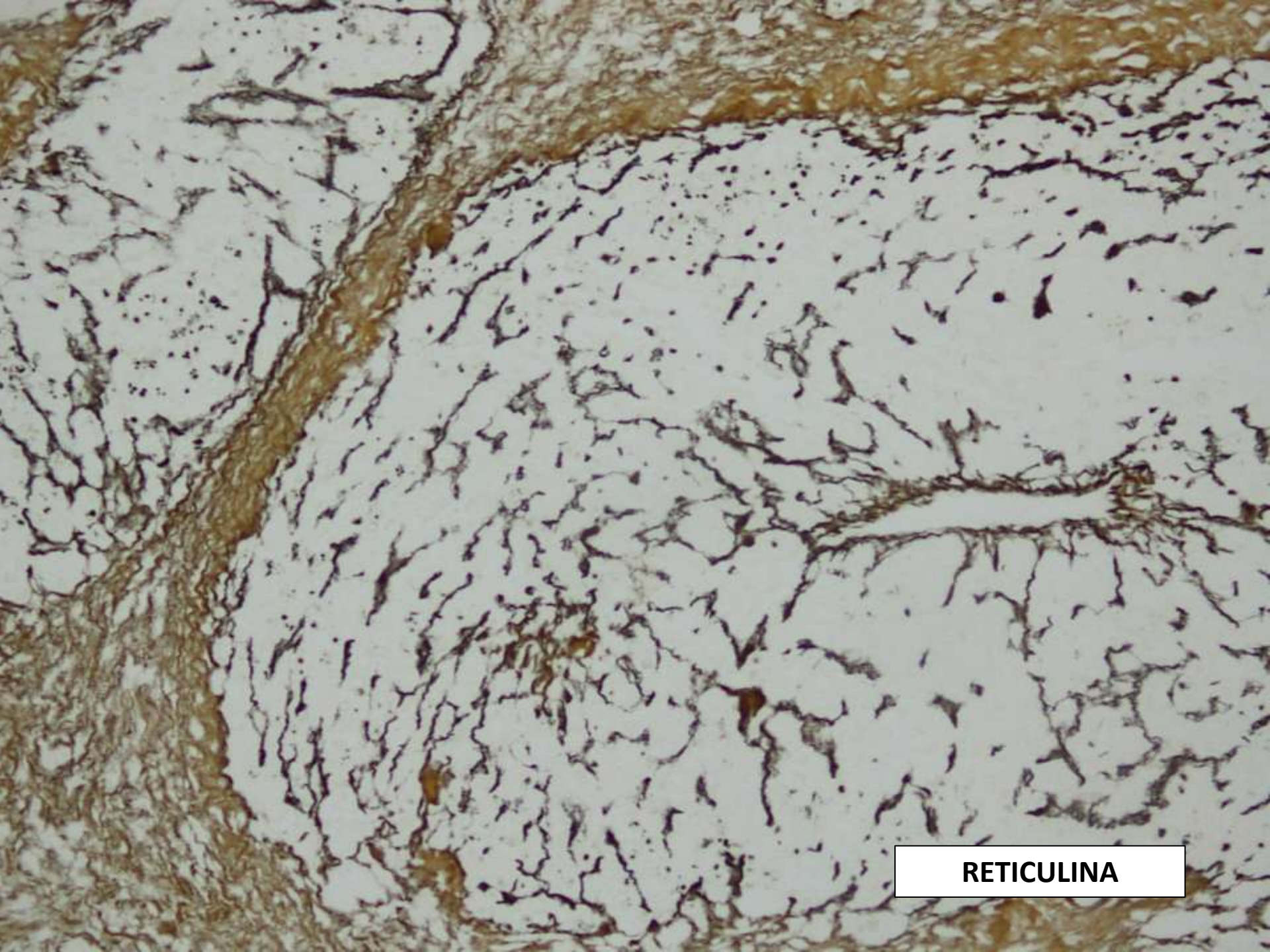
DIAGNÒSTIC INTRAOPERATORI

**Tumoració maligna,
sospitosa de
Rabdomiosarcoma com a
primera opció**

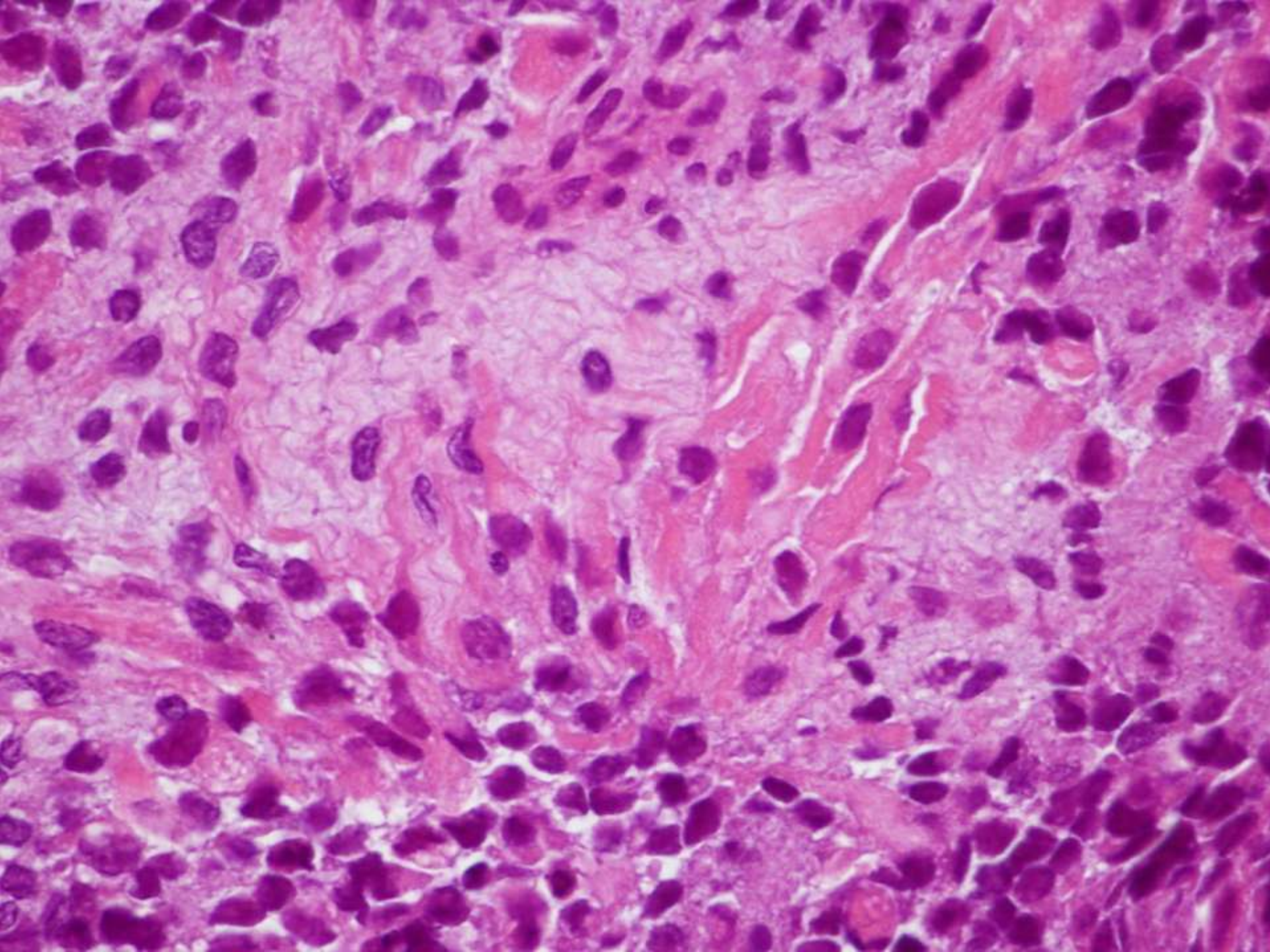


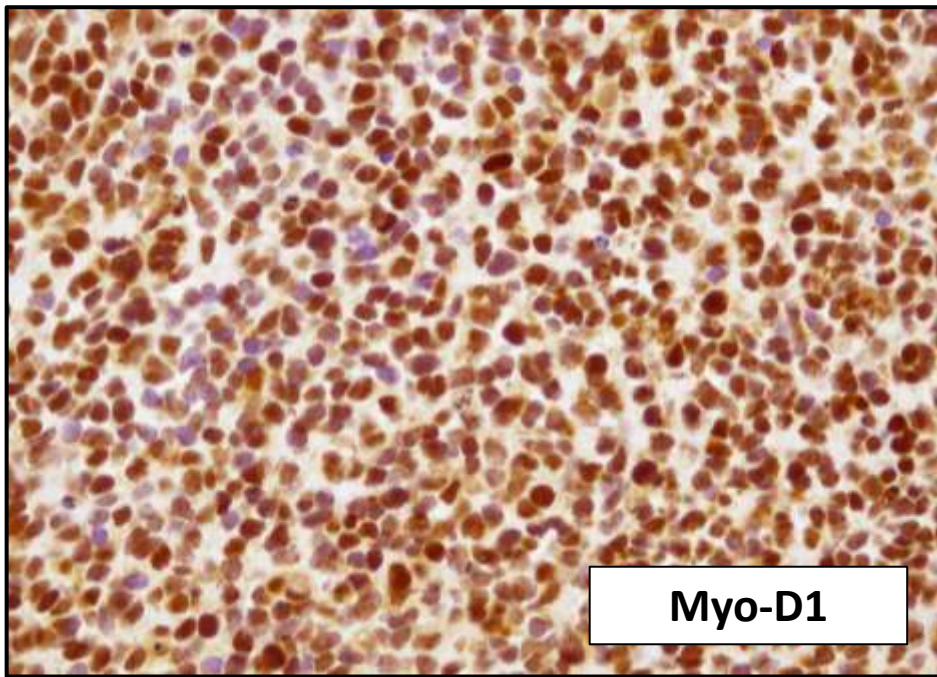
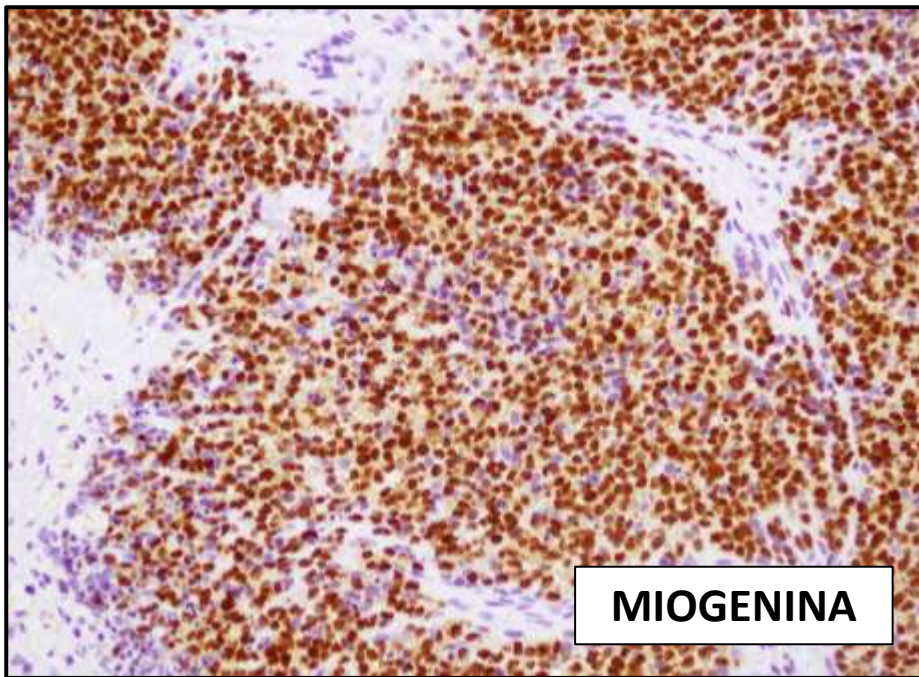
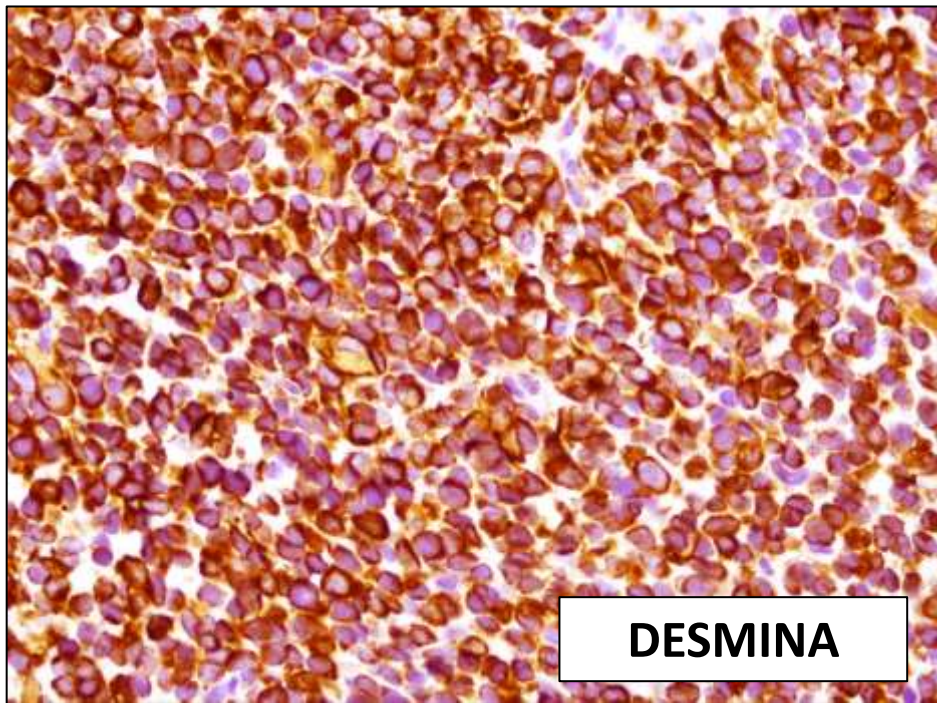
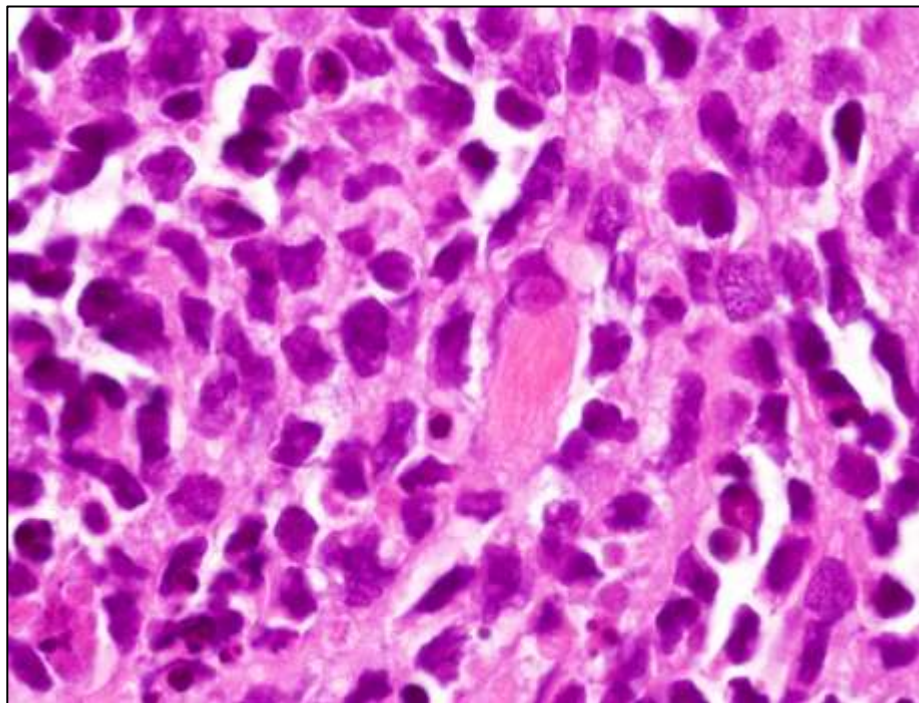






RETICULINA







DIAGNÒSTIC

Rabdomiosarcoma alveolar

Gen de fusió PAX3-FOXO1

RABDOMIOSARCOMA ALVEOLAR

- Citologia cel·lular
- Reticulina
- Immunohistoquímica
- Genètica molecular

t(2;13)(q35;q14) FOXO1-PAX3 (75%)

t(1;13)(p36;q14) FOXO1-PAX7 (5-22%)

CLASSIFICACIO INTERNACIONAL RMS 1996

- **Pronòstic favorable**

 - Rabdomiosarcoma botrioide

 - Rabdomiosarcoma fusocel·lular

- **Pronòstic intermig**

 - Rabdomiosarcoma embrionari

- **Pronòstic desfavorable**

 - Rabdomiosarcoma alveolar

 - Sarcoma indiferenciat



CLASSIFICACIO WHO 2013

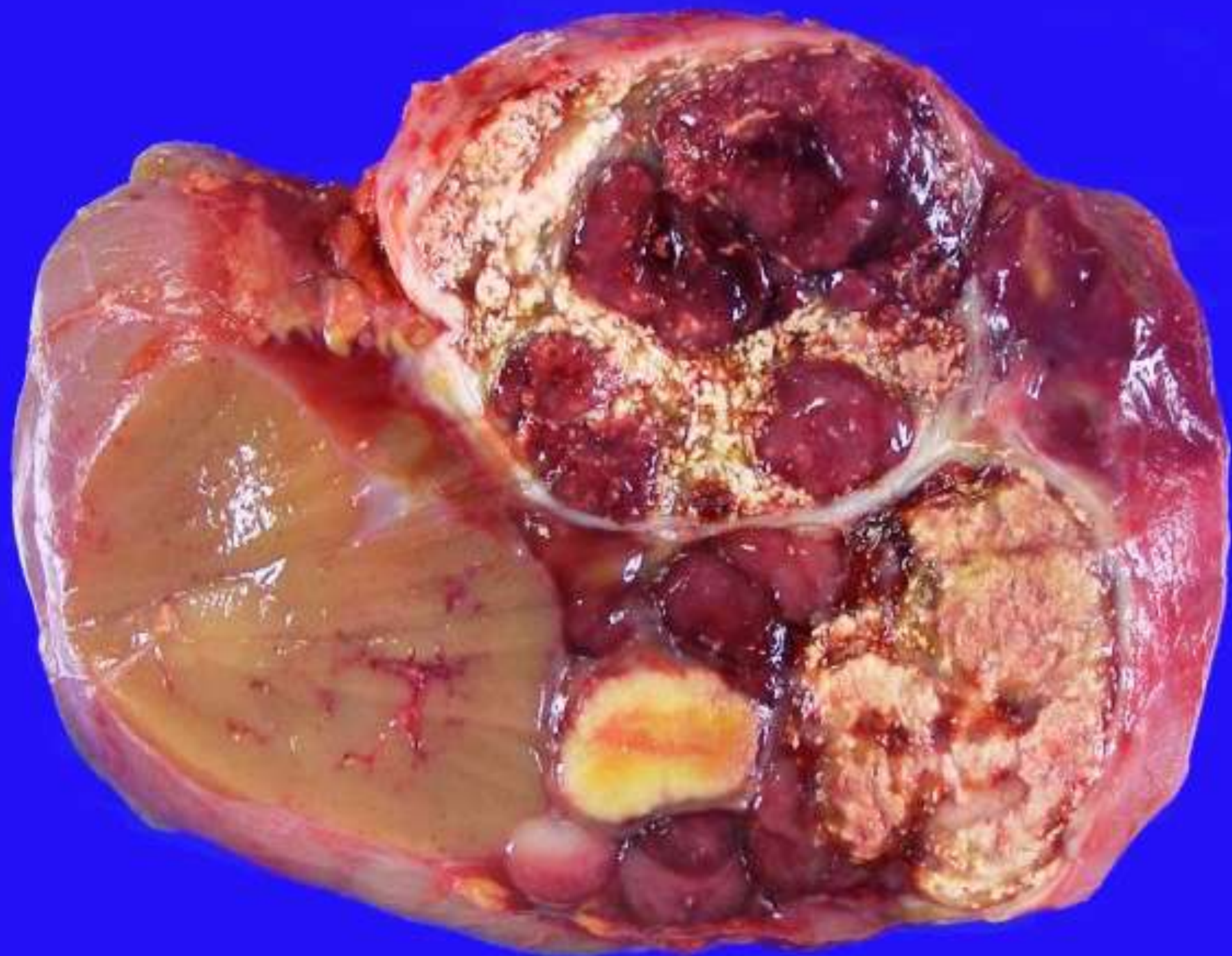- Rabdomiosarcoma embrionari (inclou botrioide)
- Rabdomiosarcoma alveolar
- Rabdomiosarcoma pleomòrfic
- Rabdomiosarcoma fusocel·lular/esclerosant

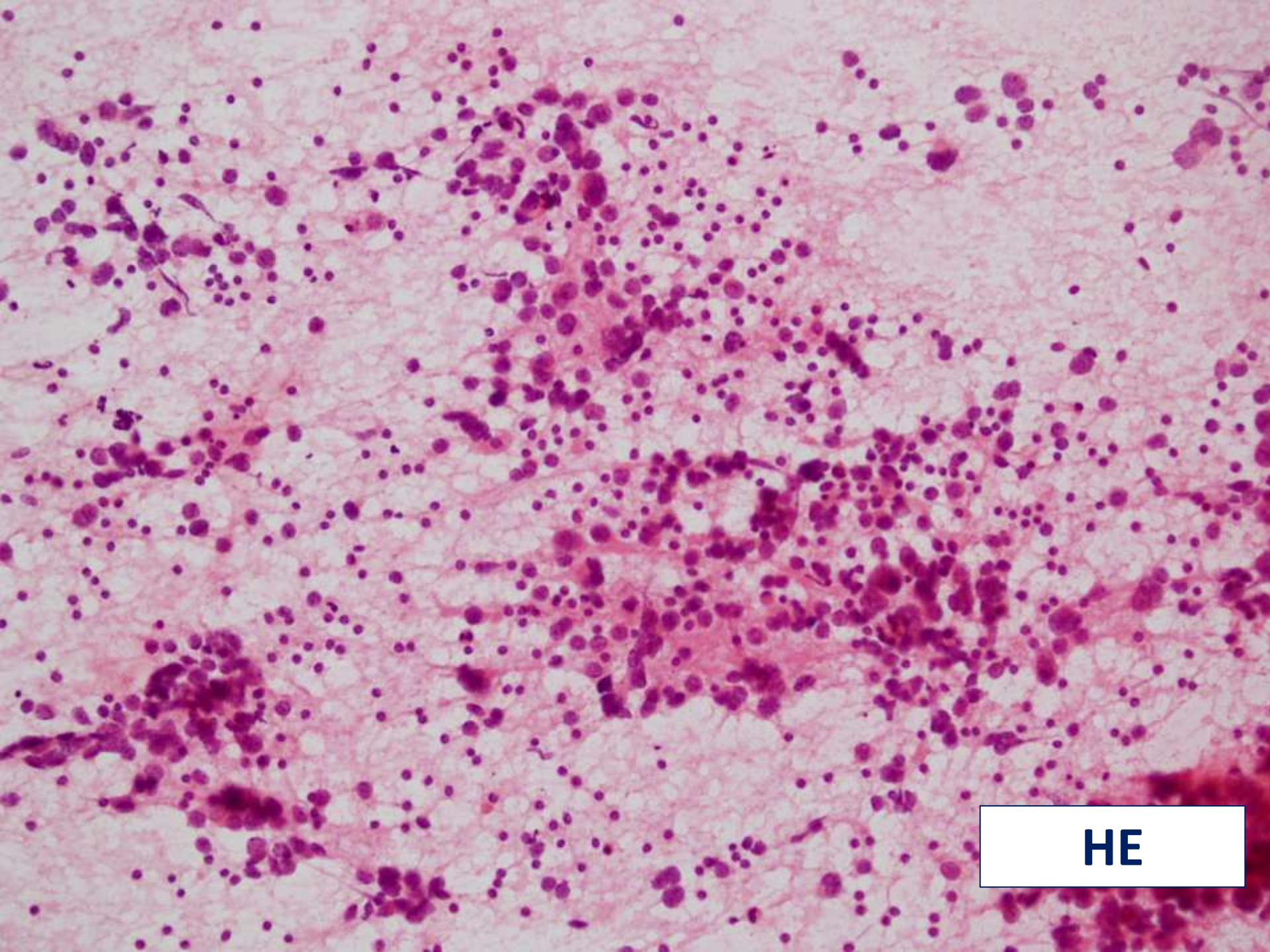
DIAGNÒSTIC DIFERENCIAL

Tumors indiferenciats de cèl·lula rodona

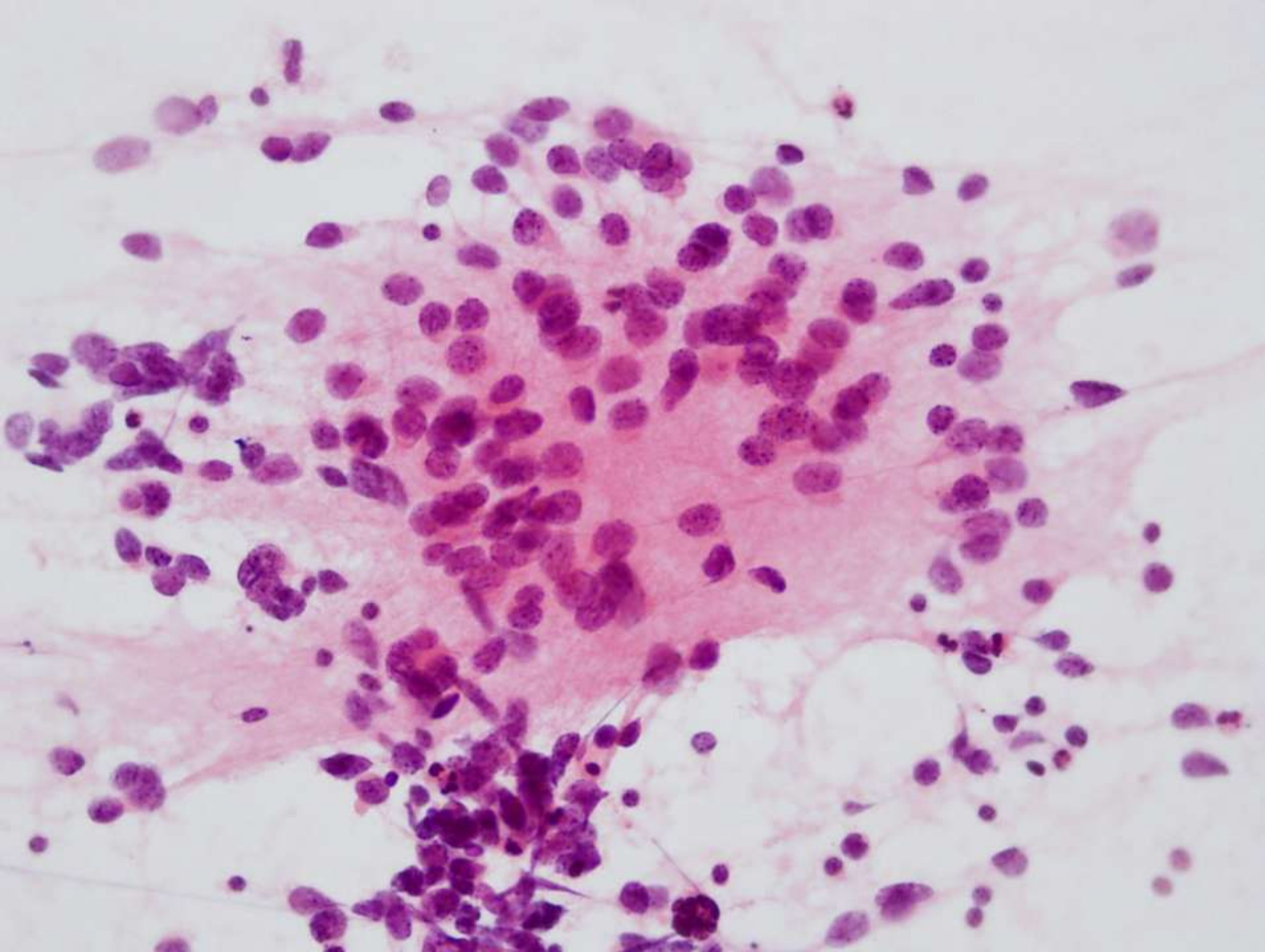
- **Sarcoma Ewing/PNET**
- **Linfoma**
- **Neuroblastoma**
- **Nefroblastoma**
- **Sarcoma sinovial**

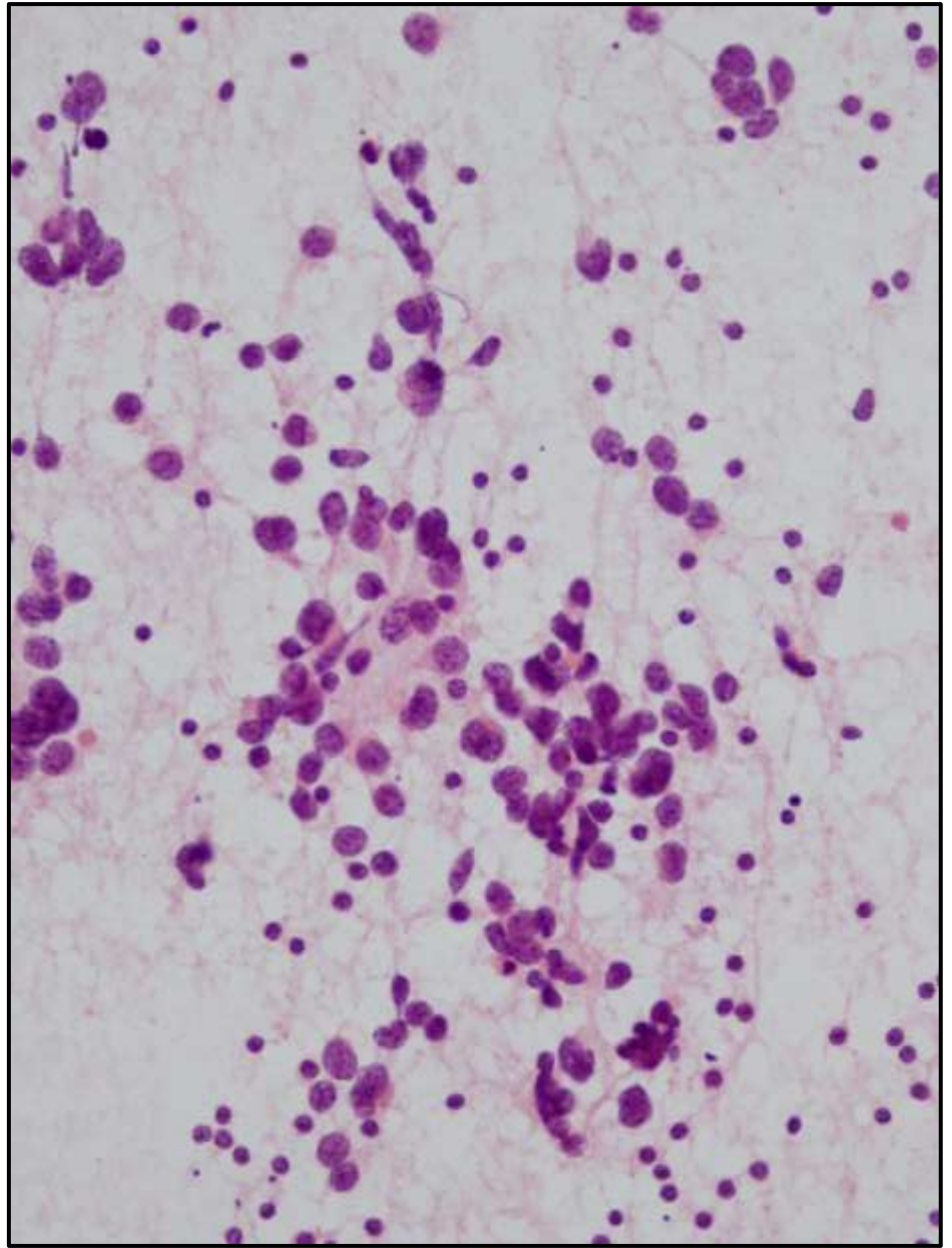
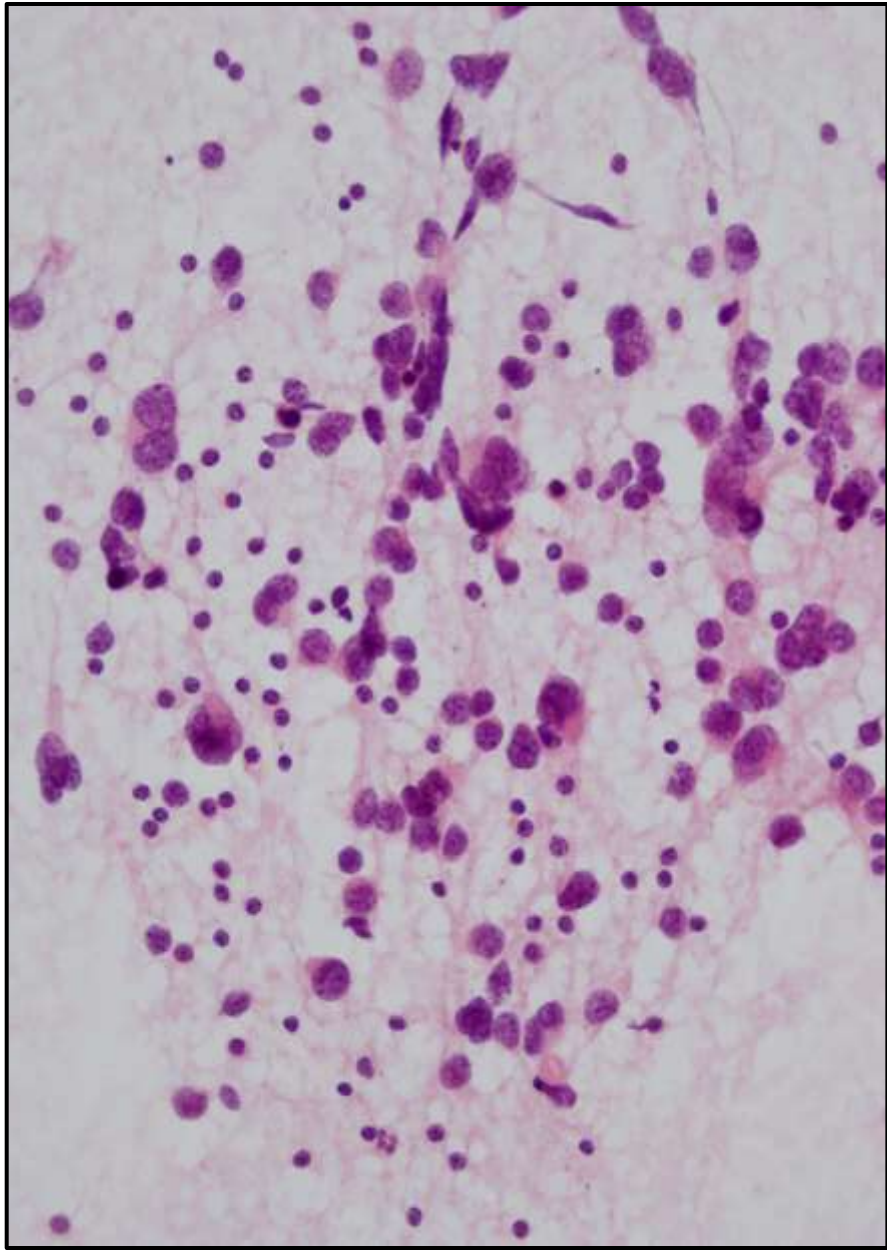
NEUROBLASTOMA

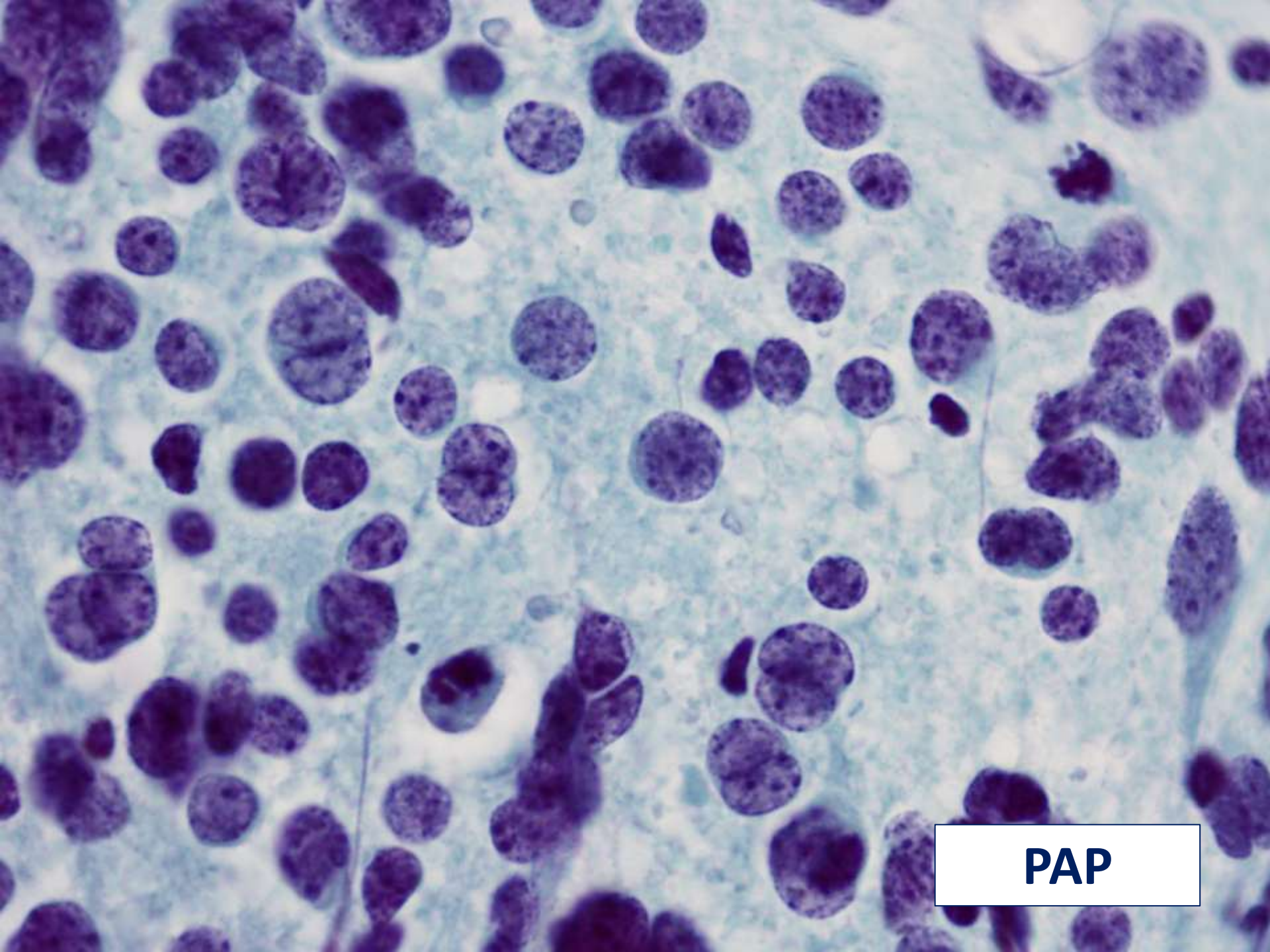




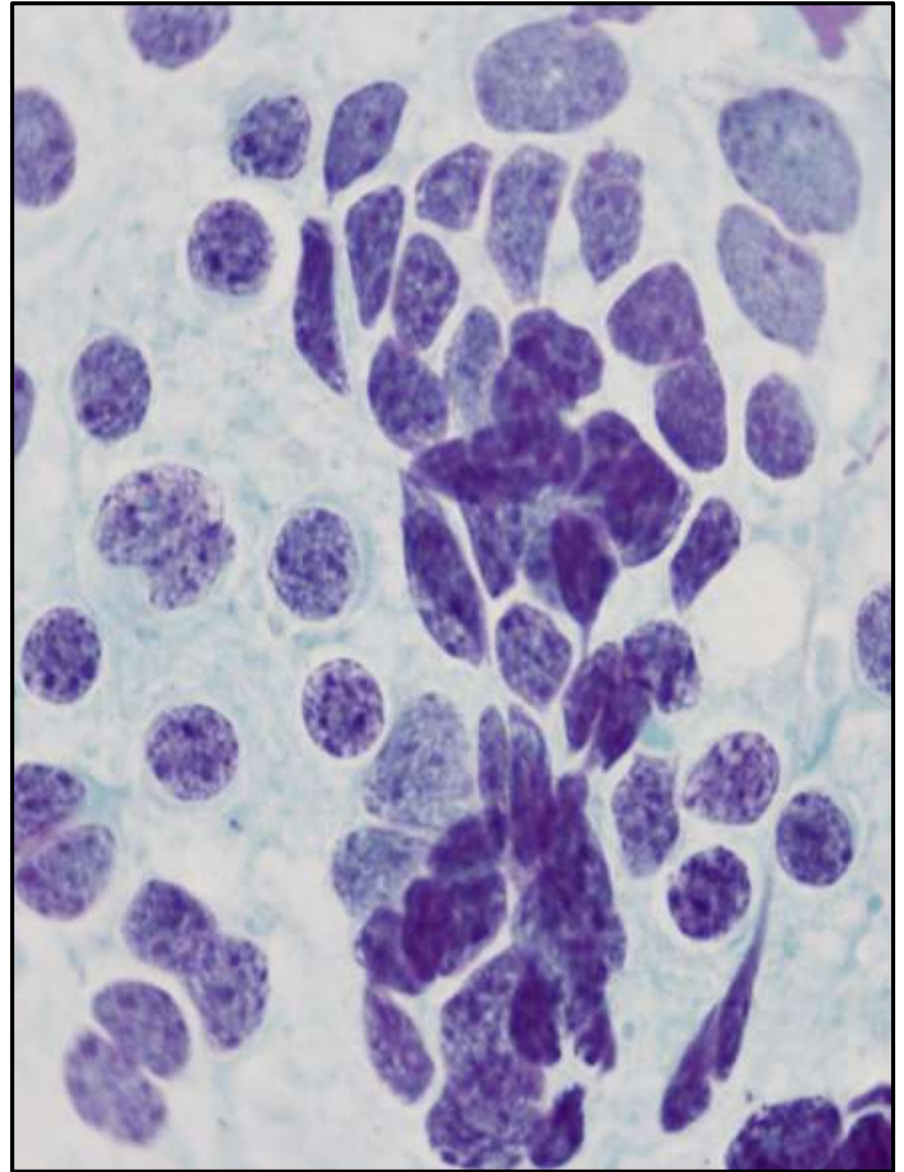
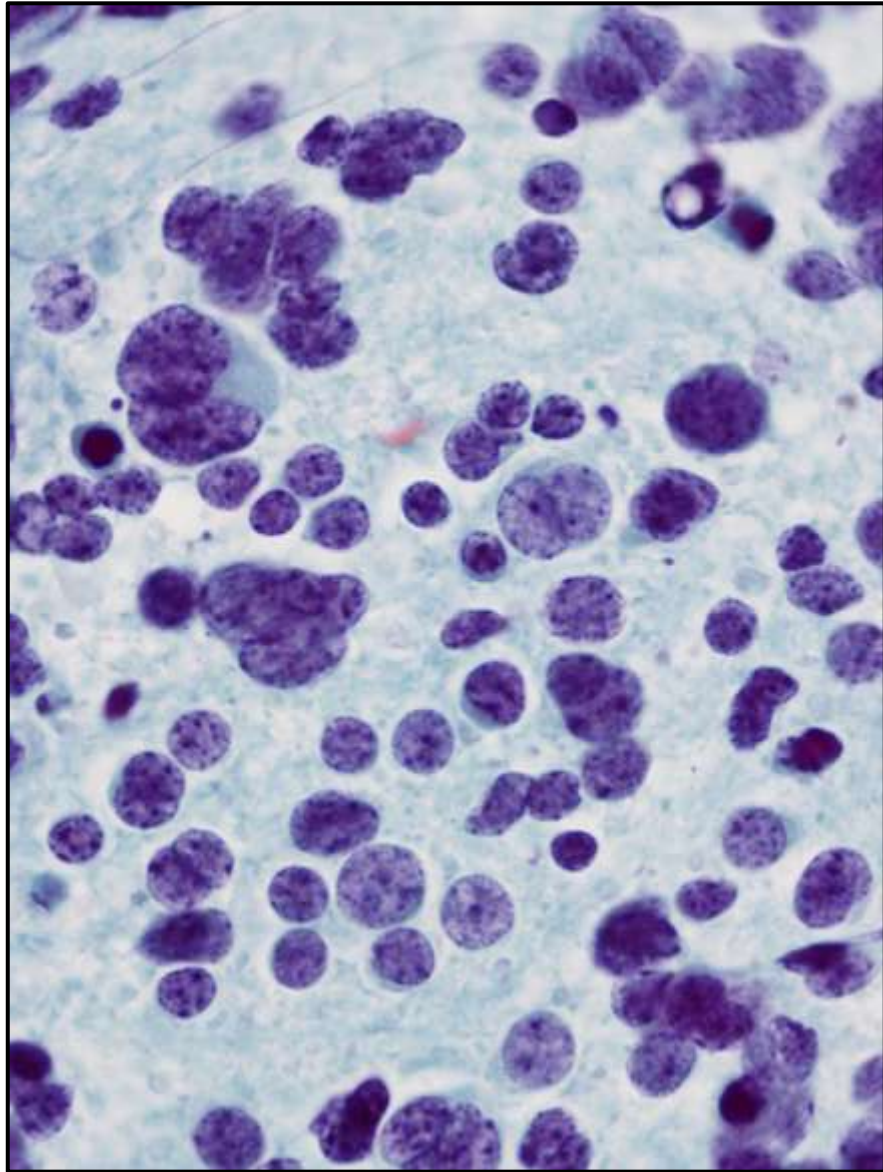
HE

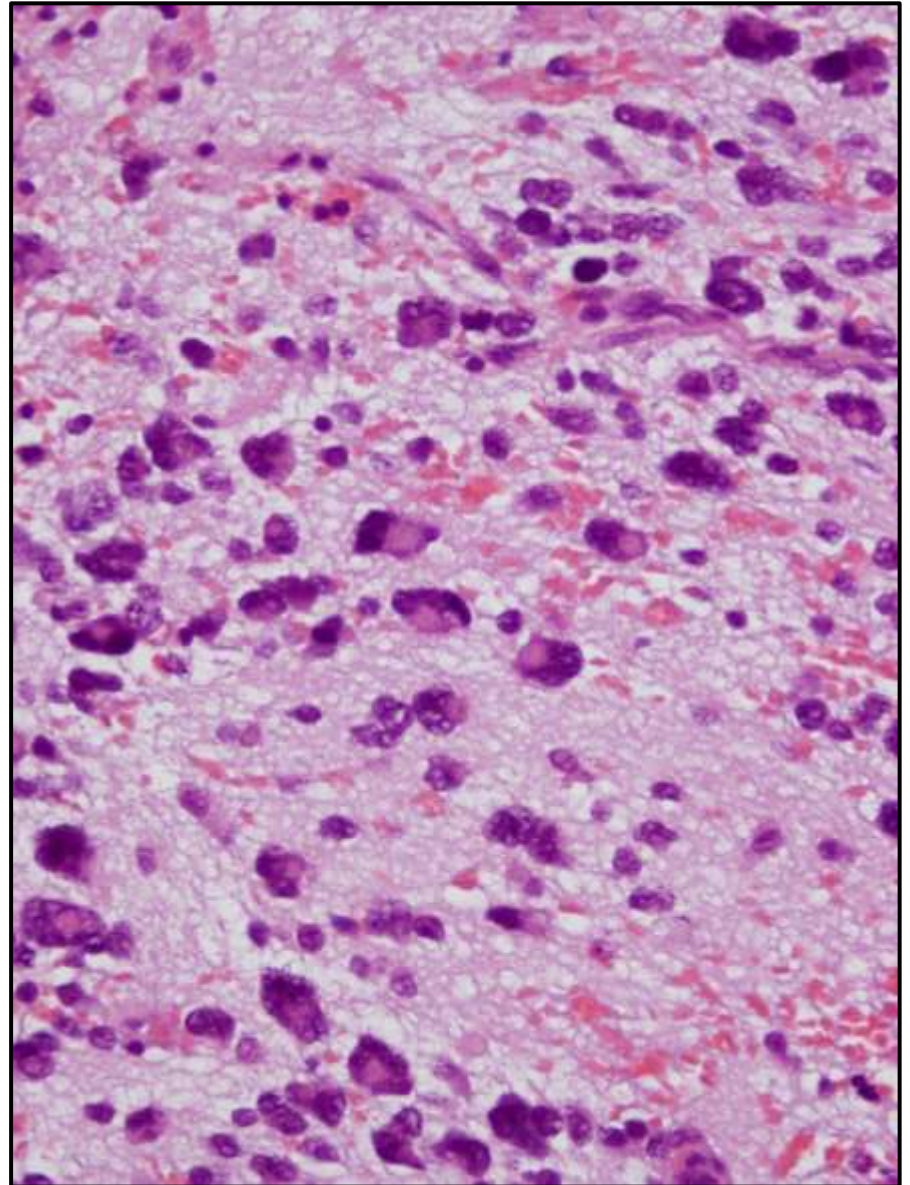
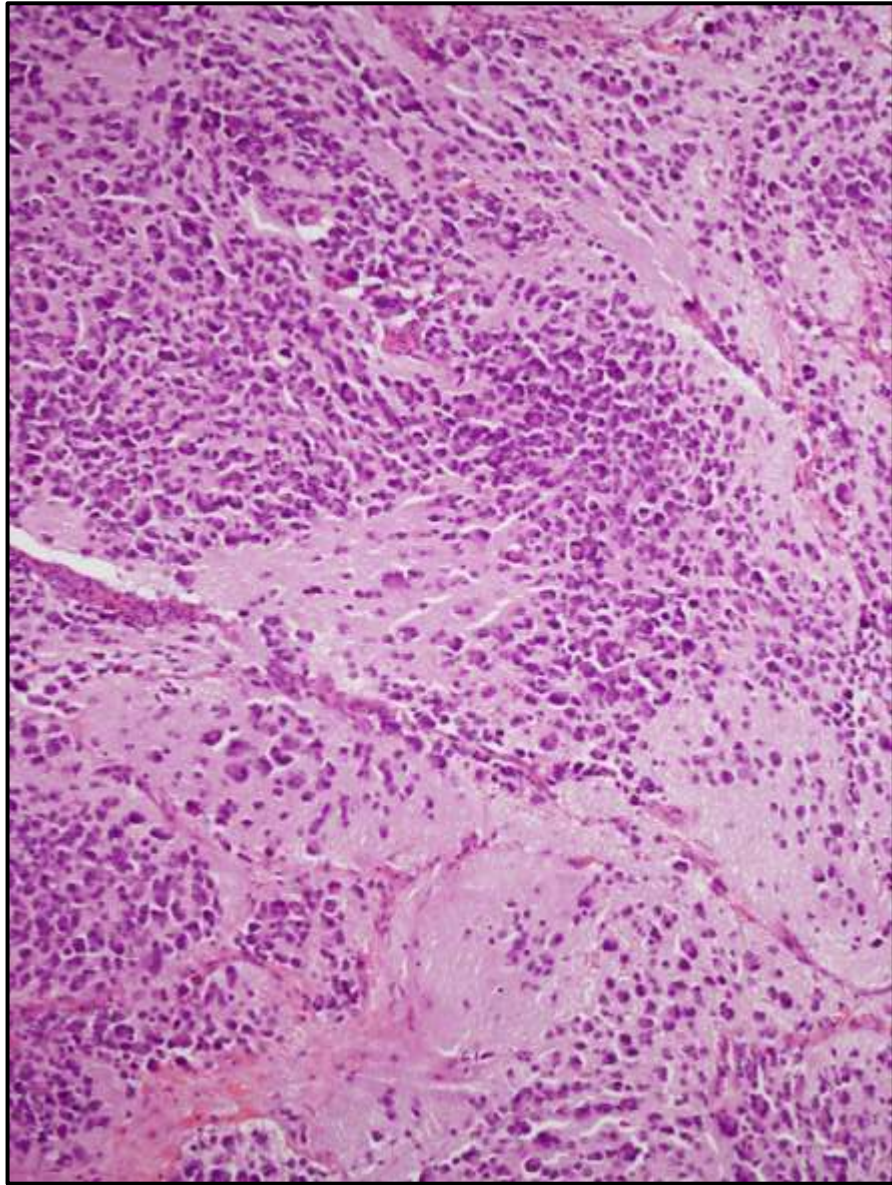


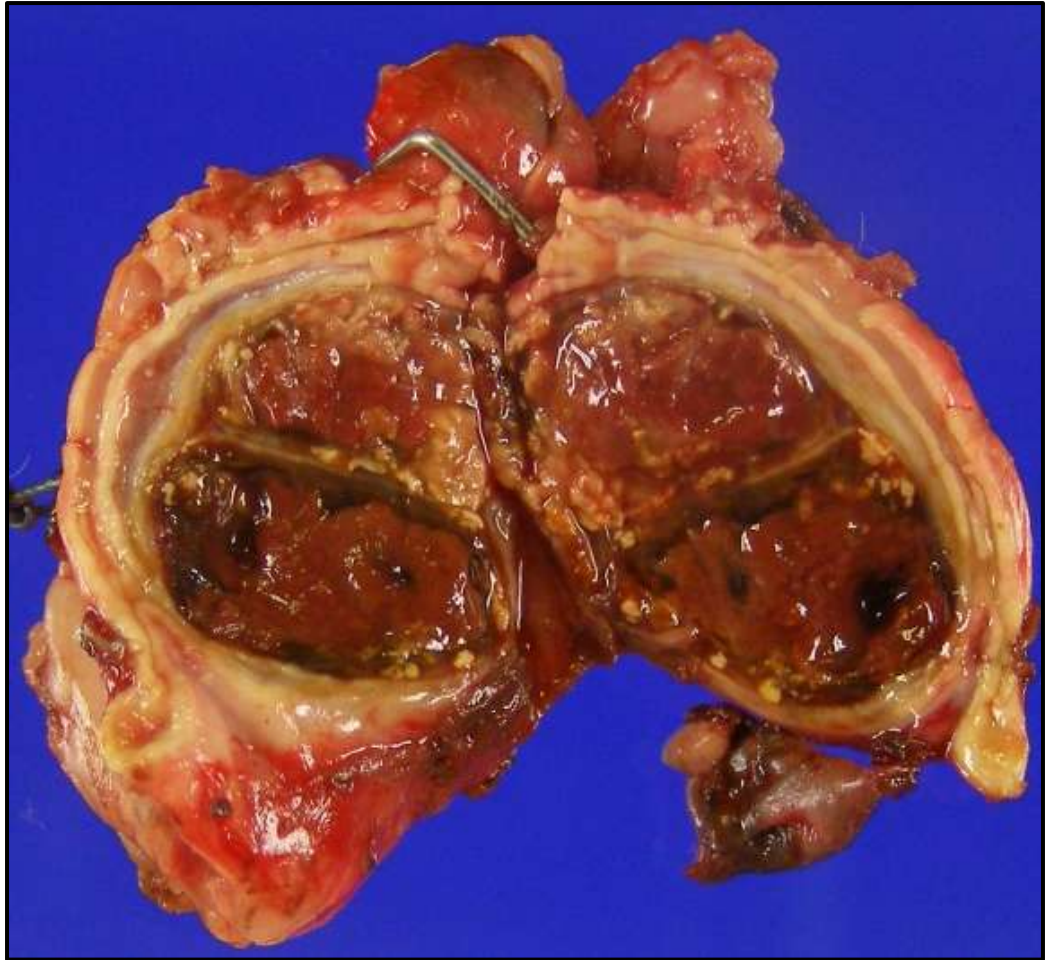
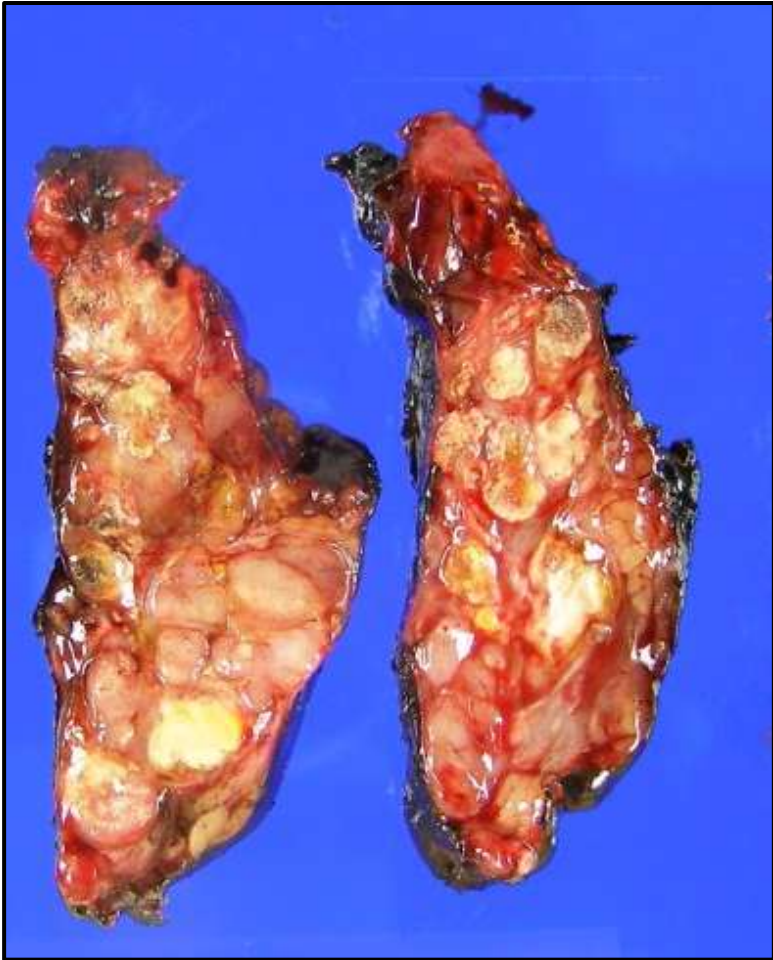

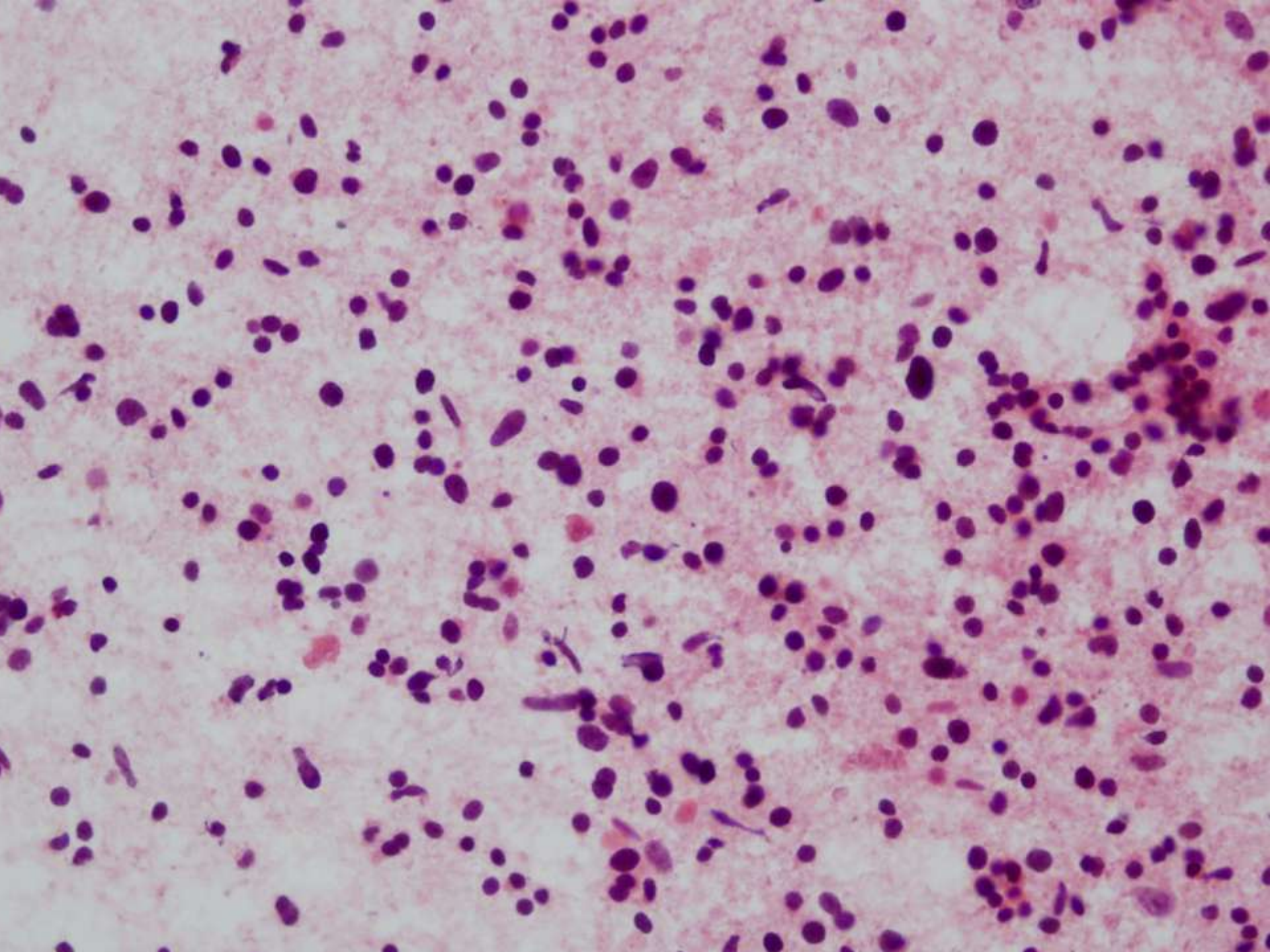


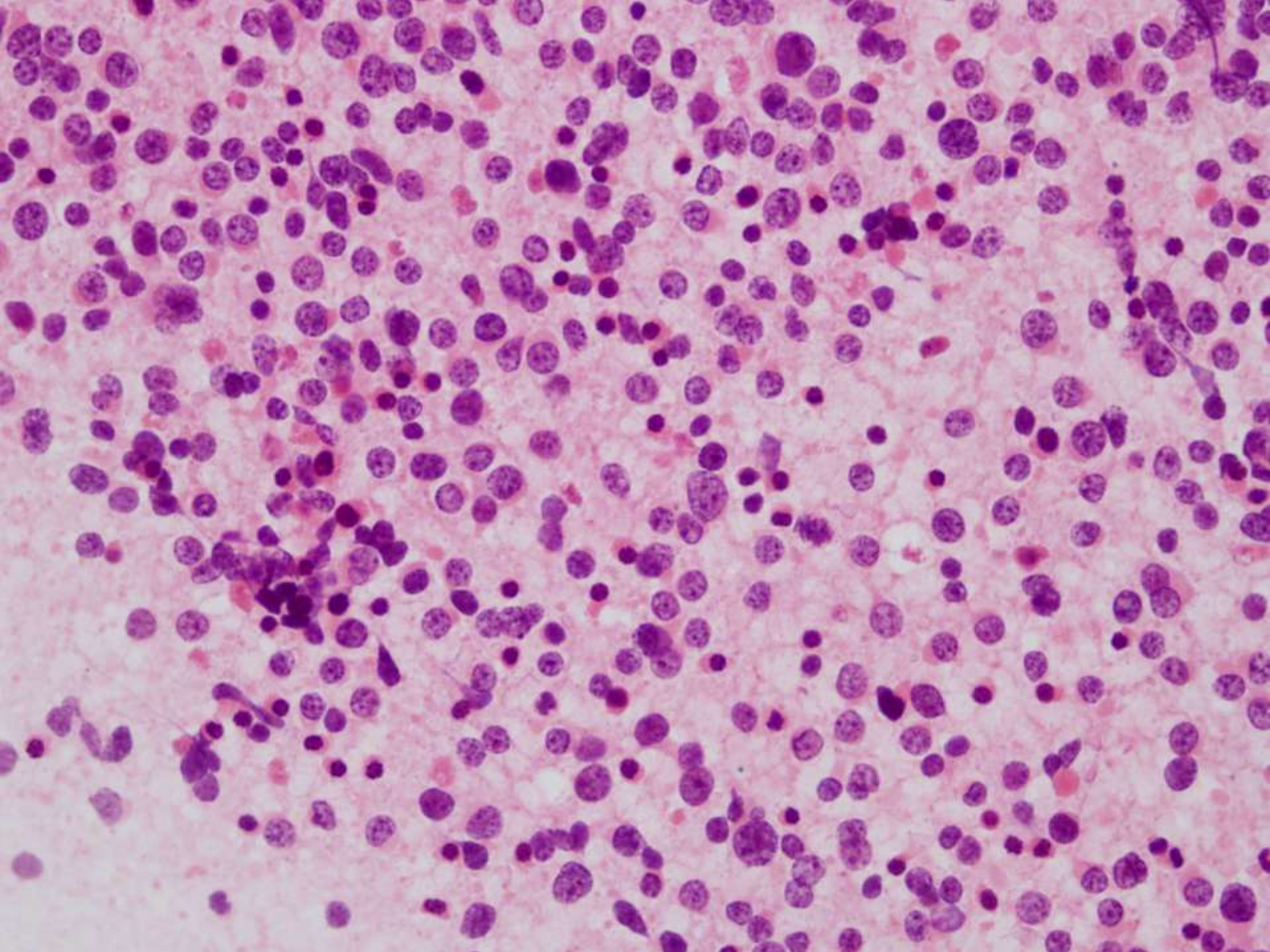
PAP

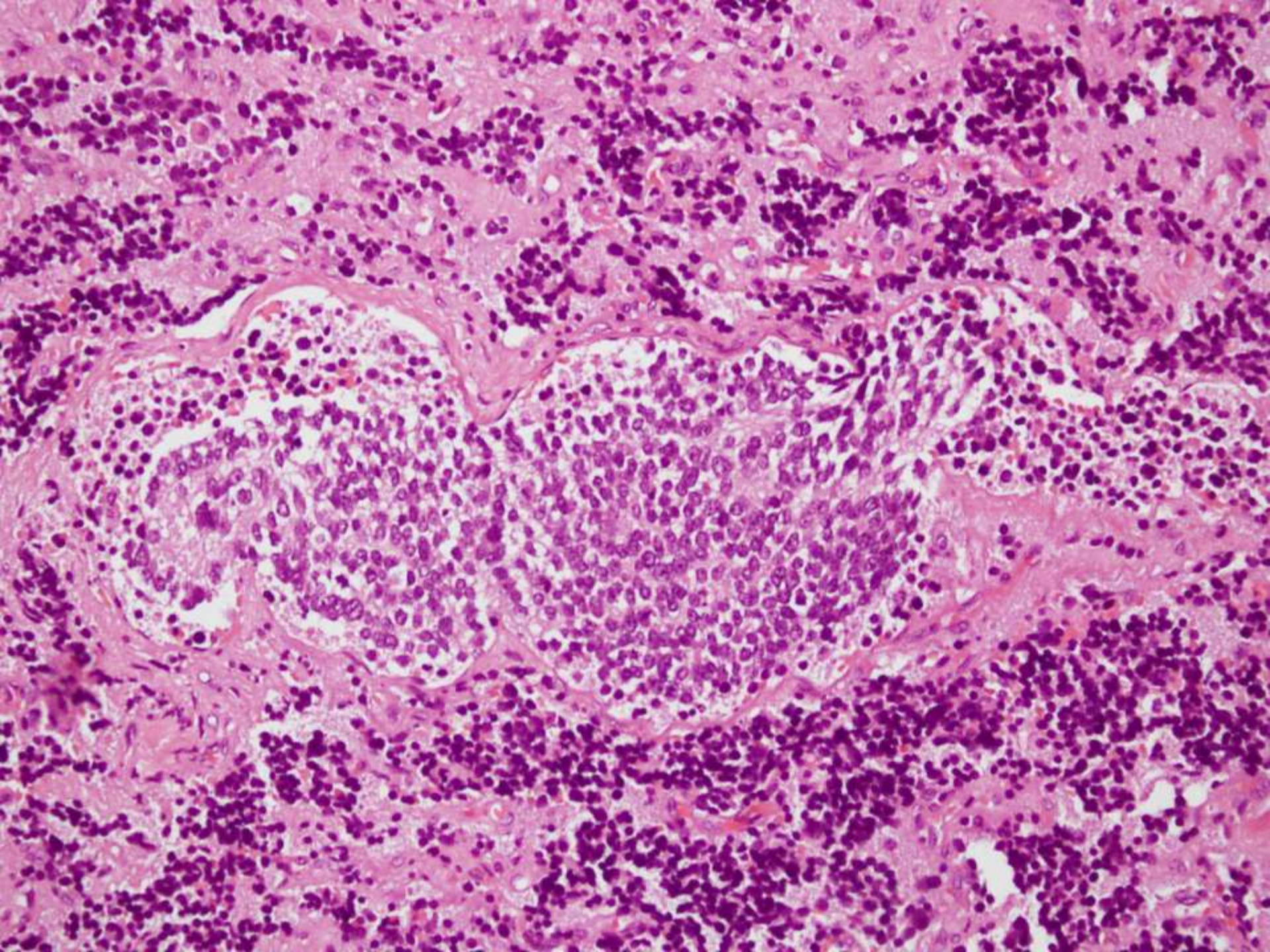




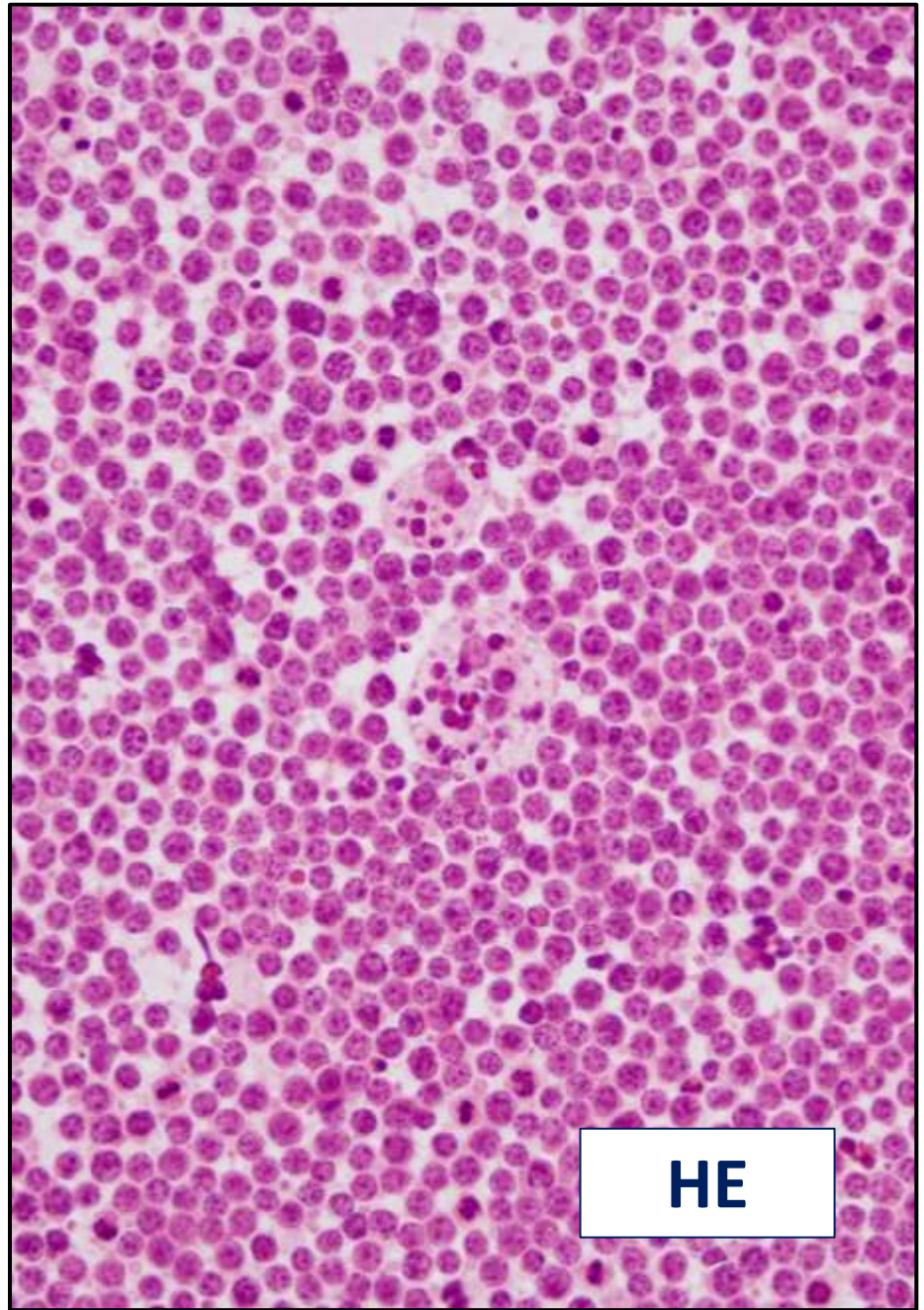
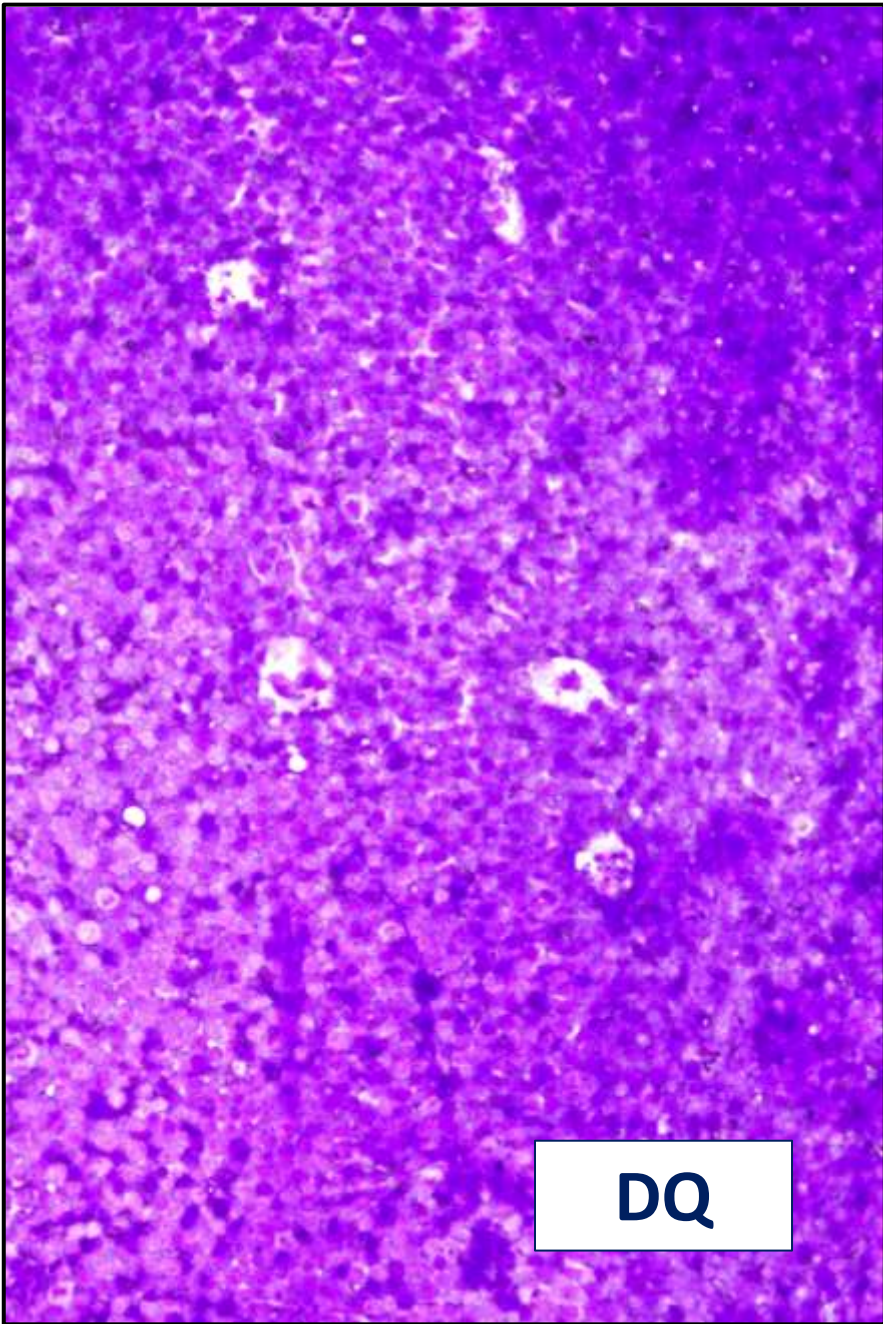


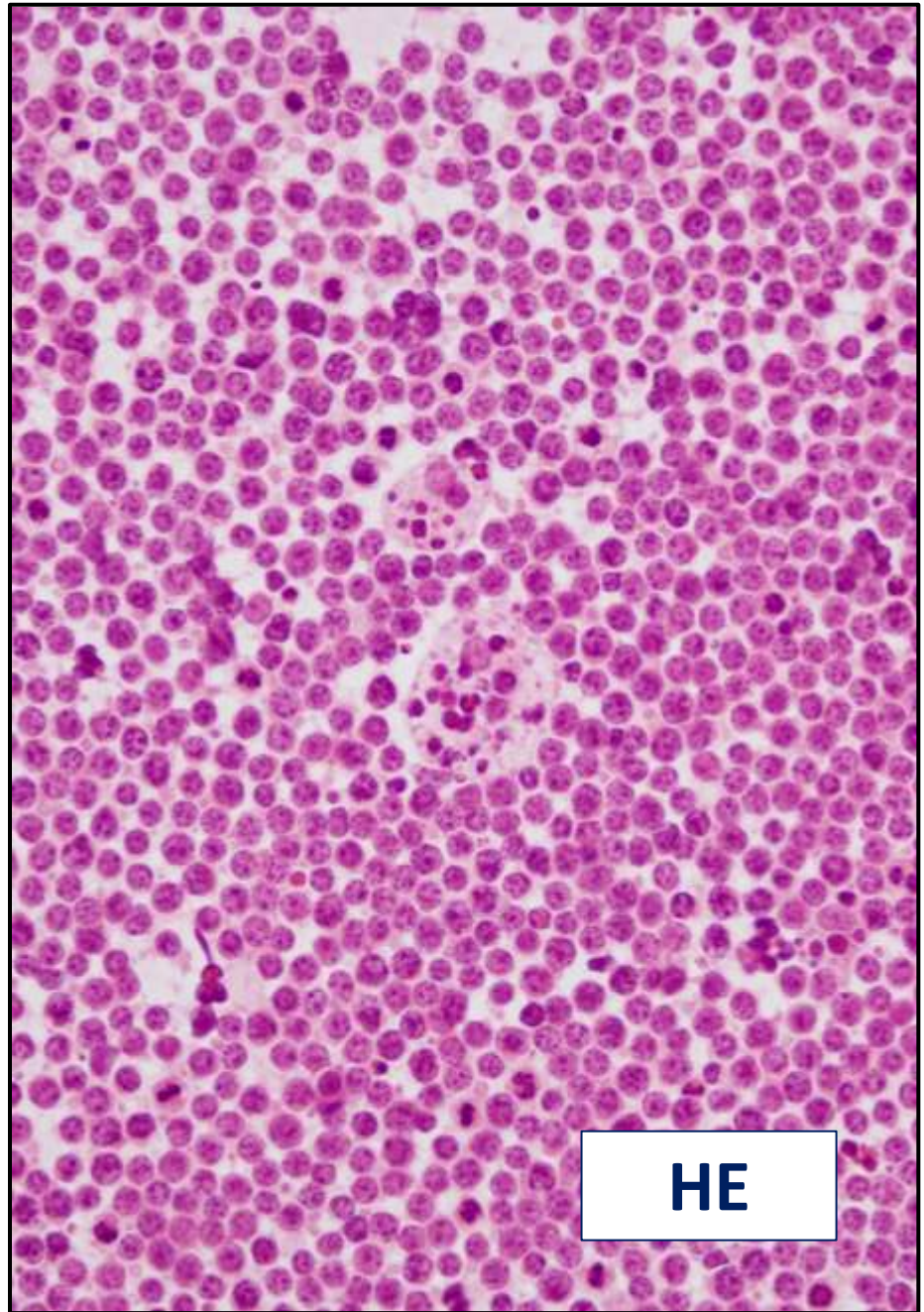
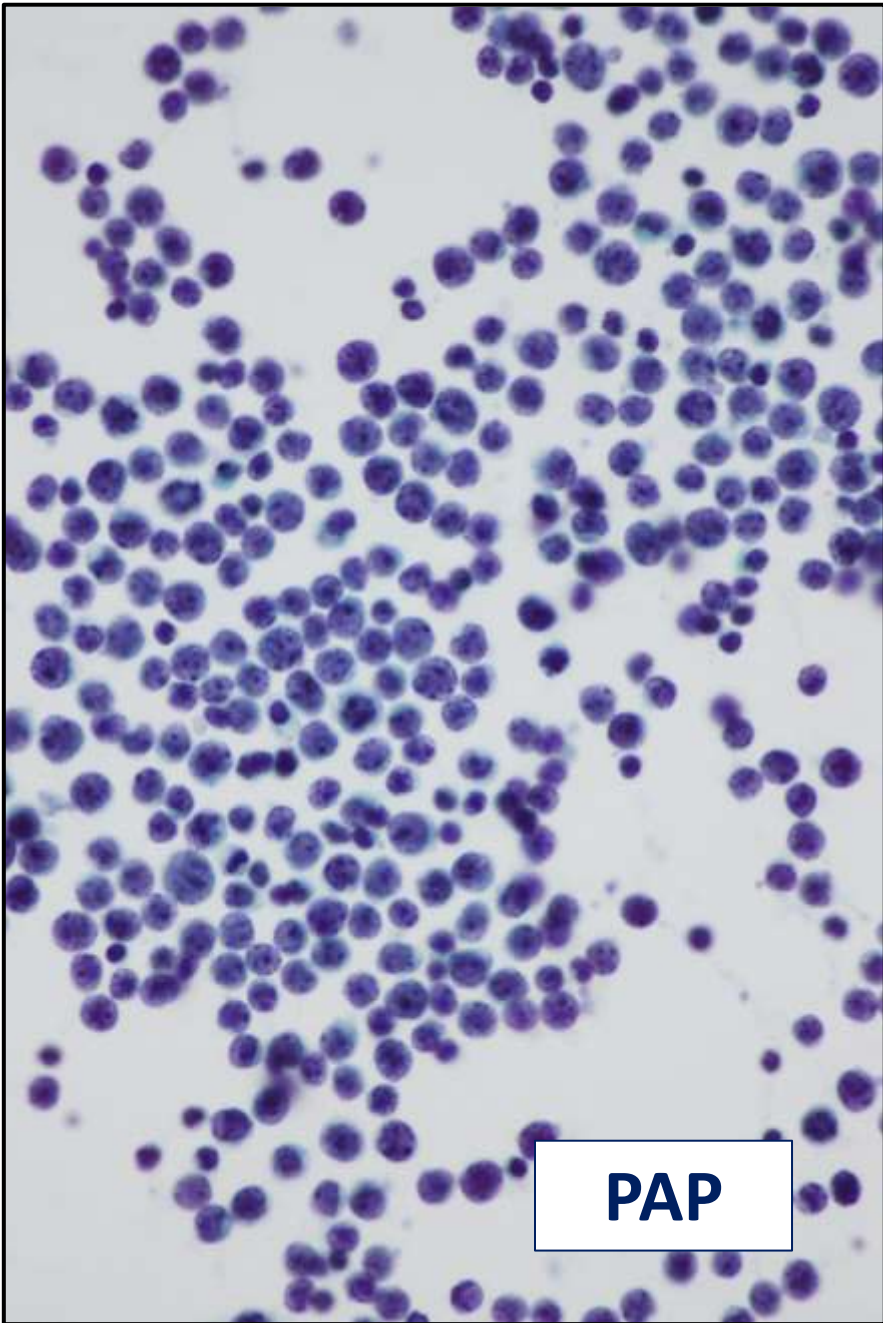


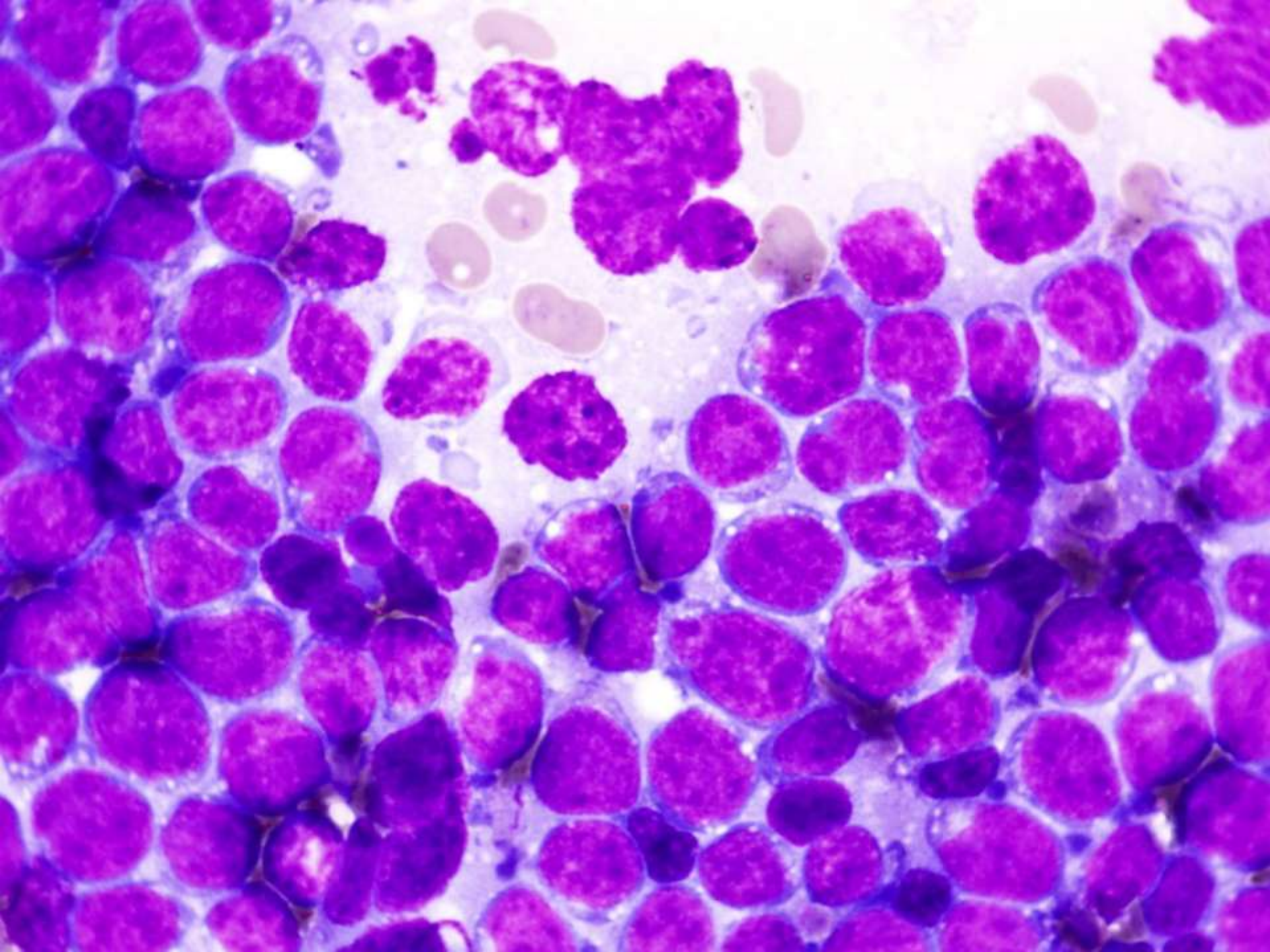


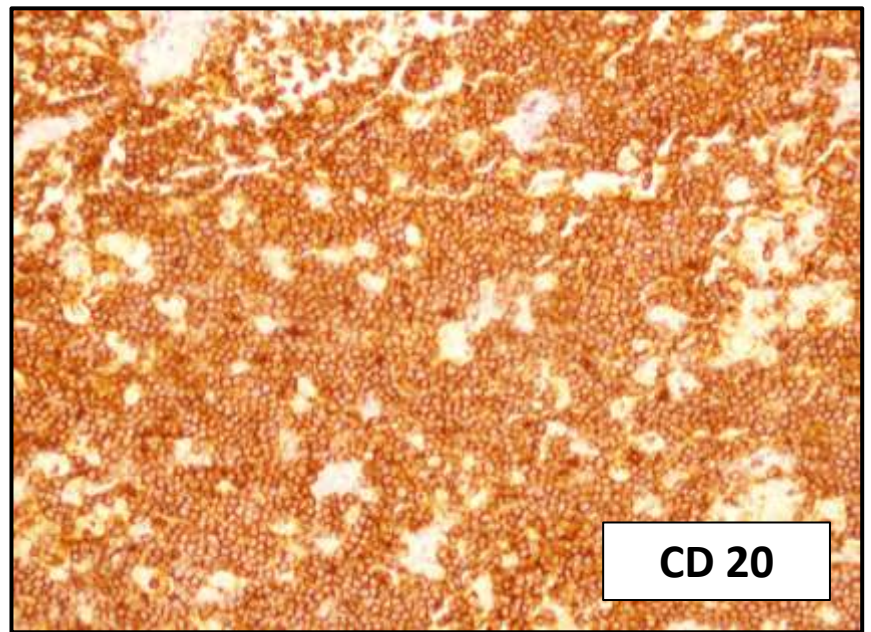

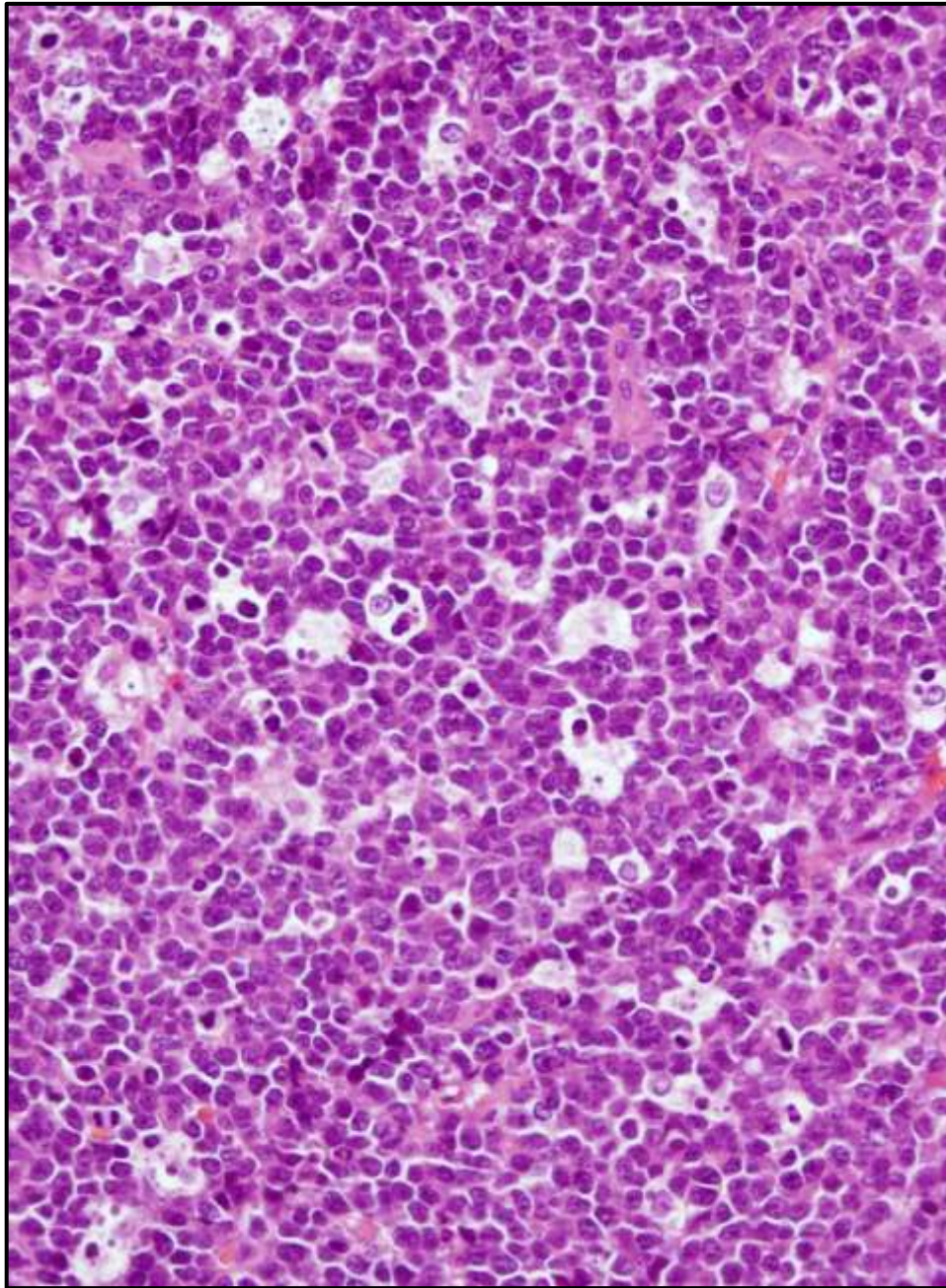


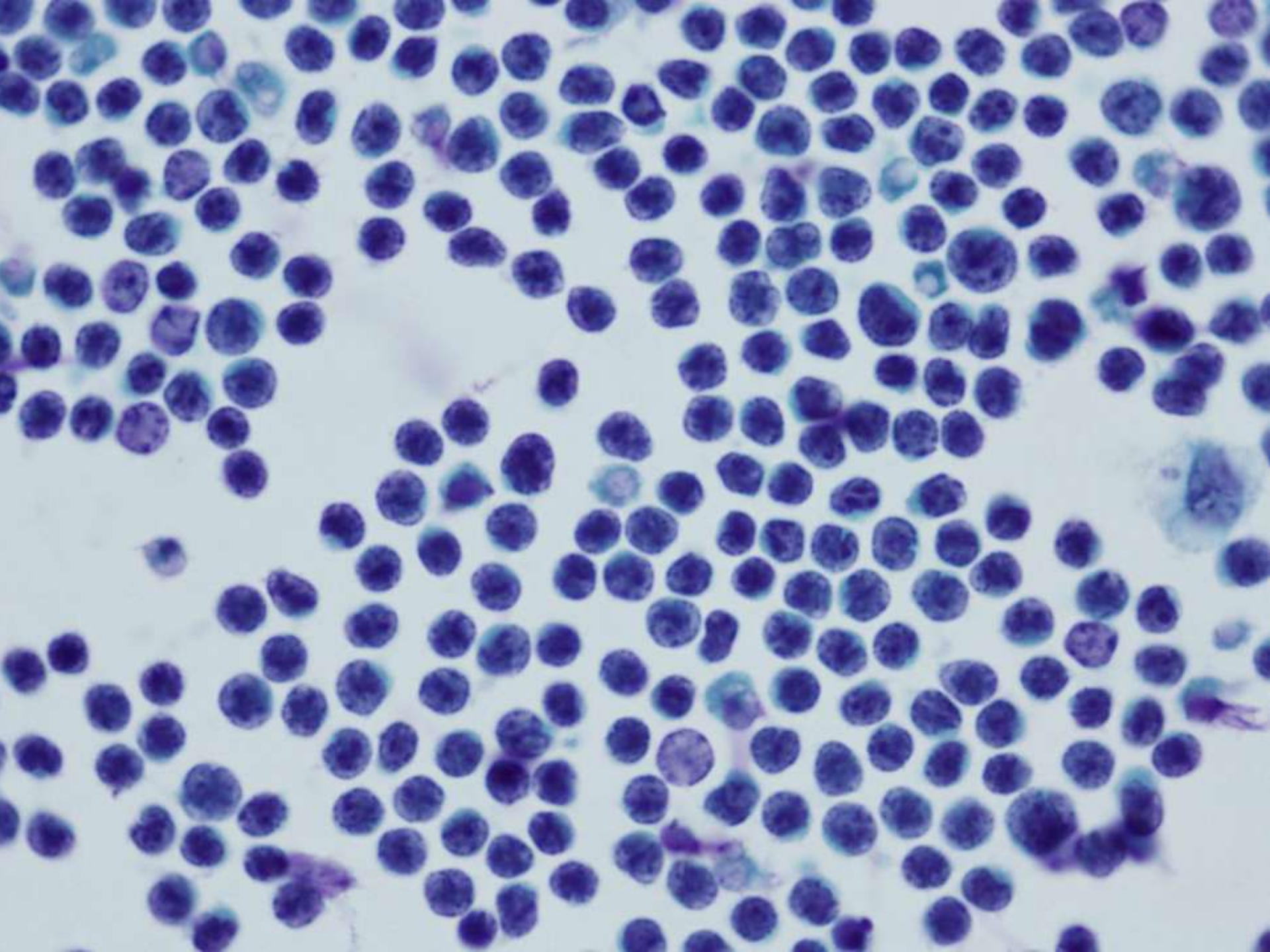
PROCESSOS LIMFOPROLIFERATIVUS

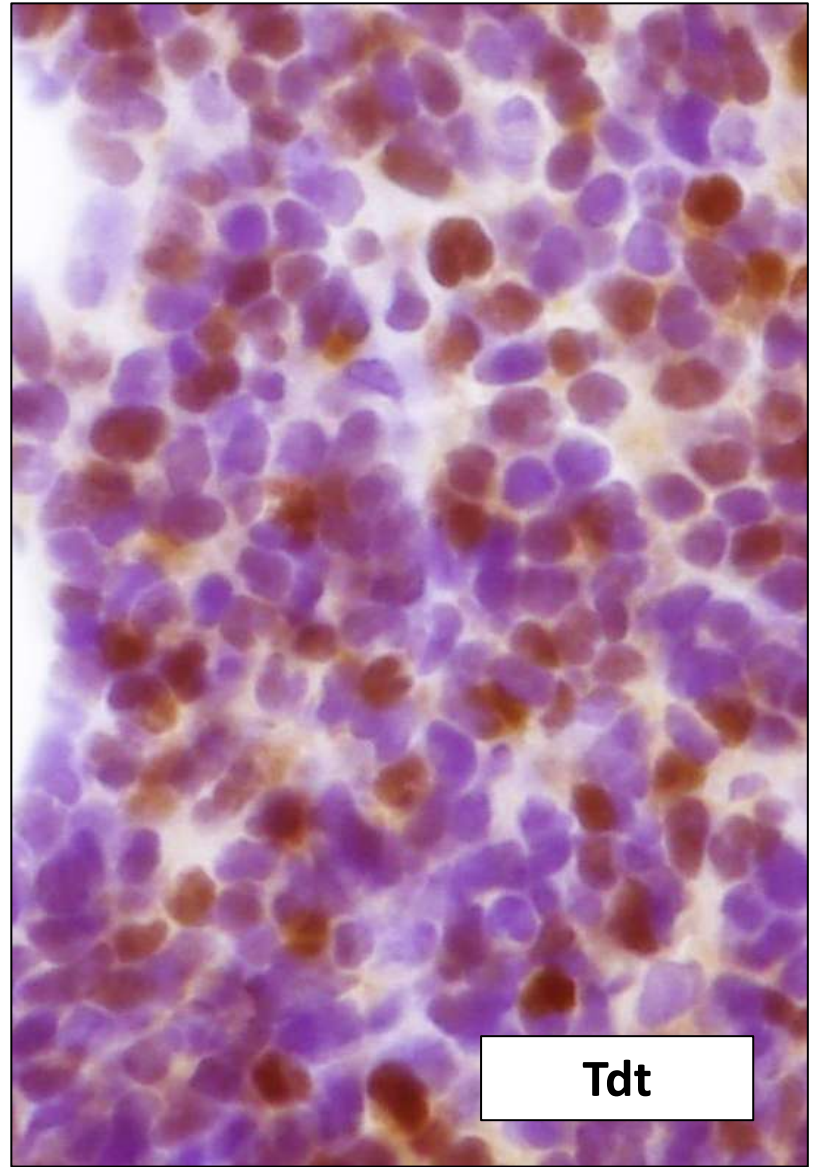
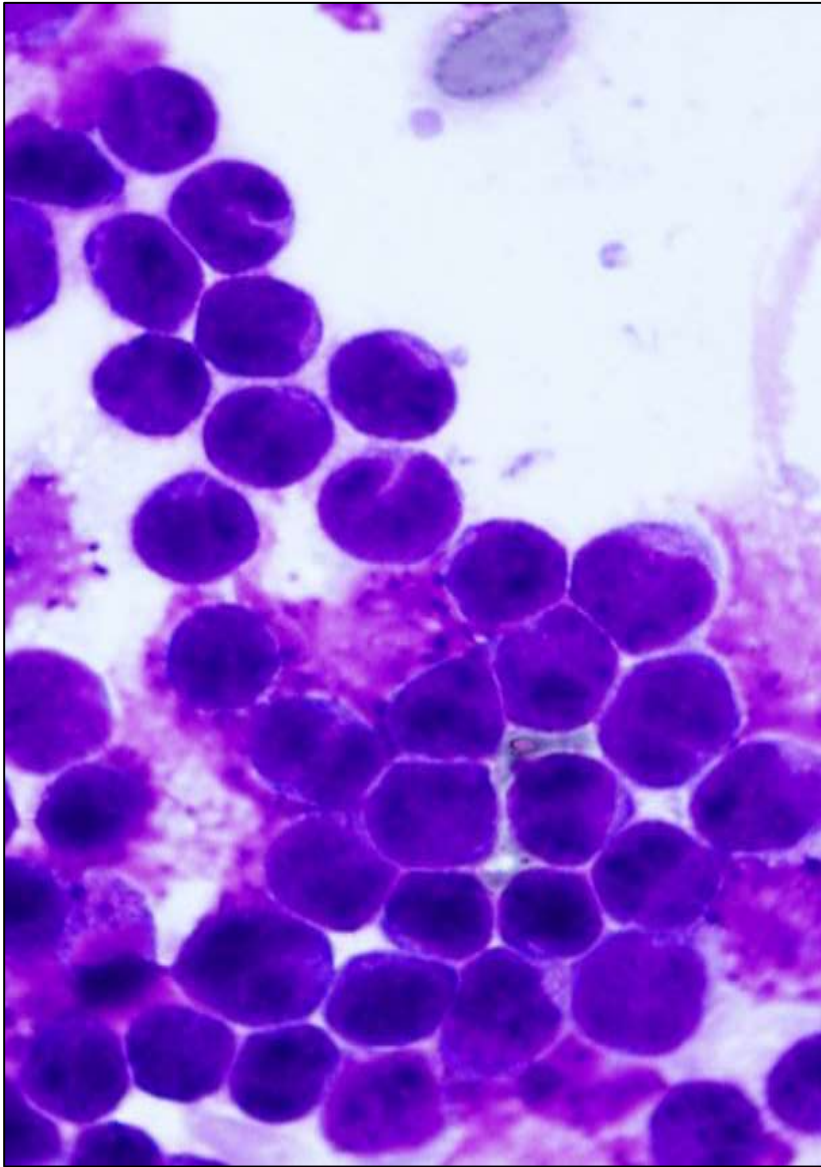






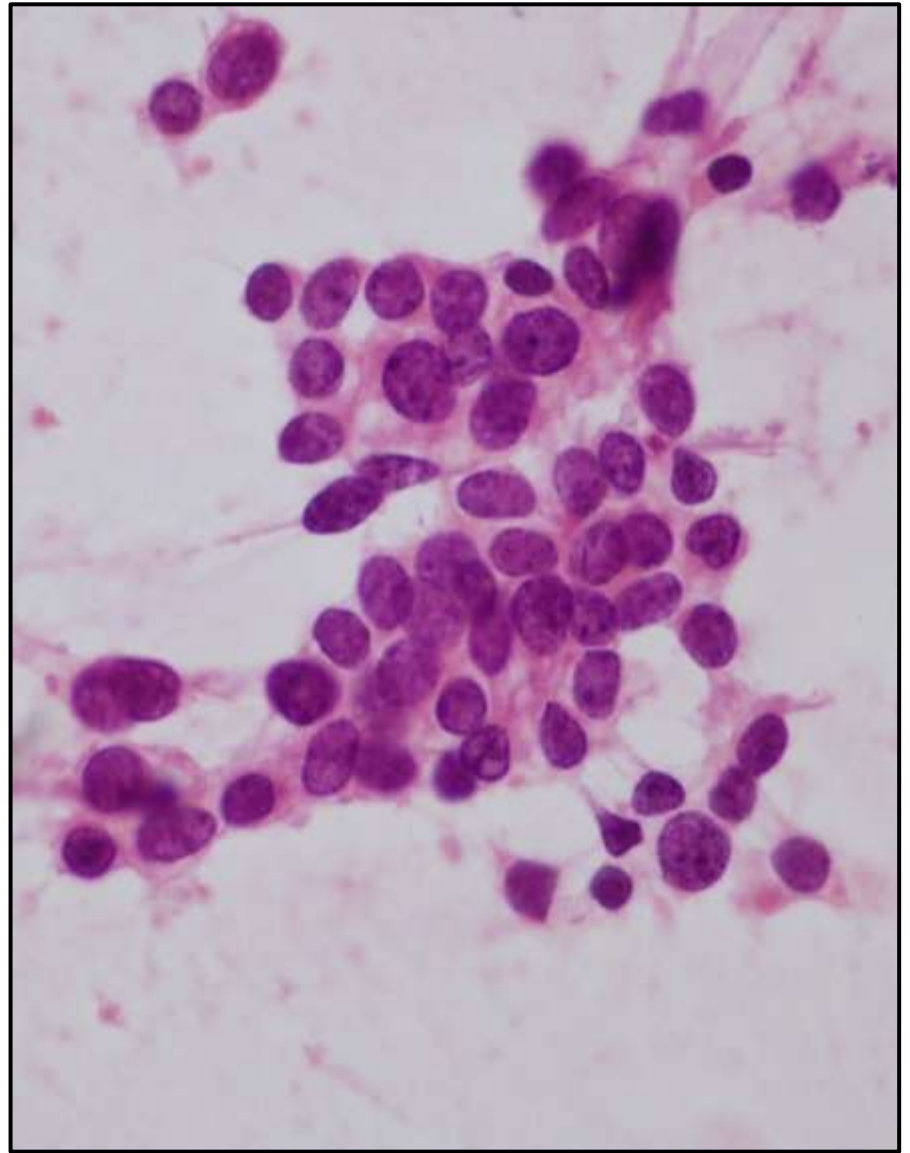
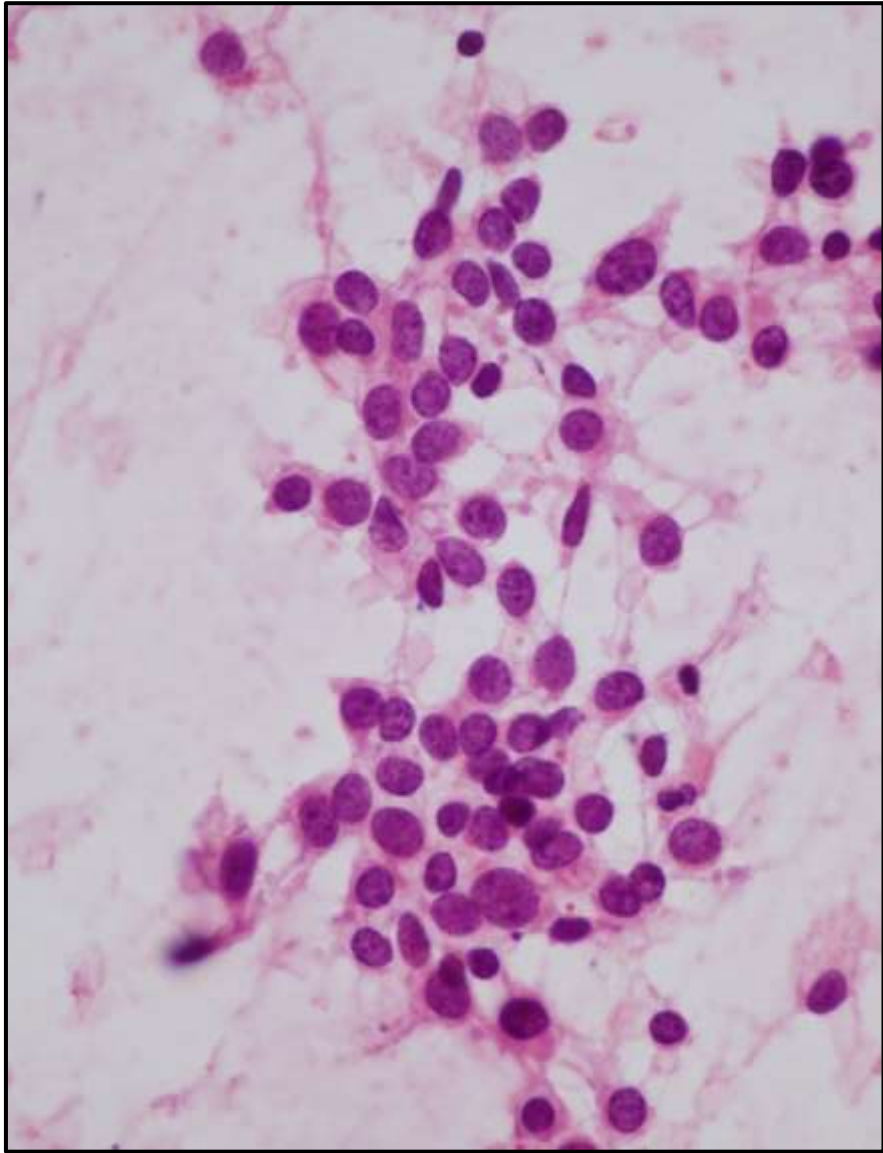




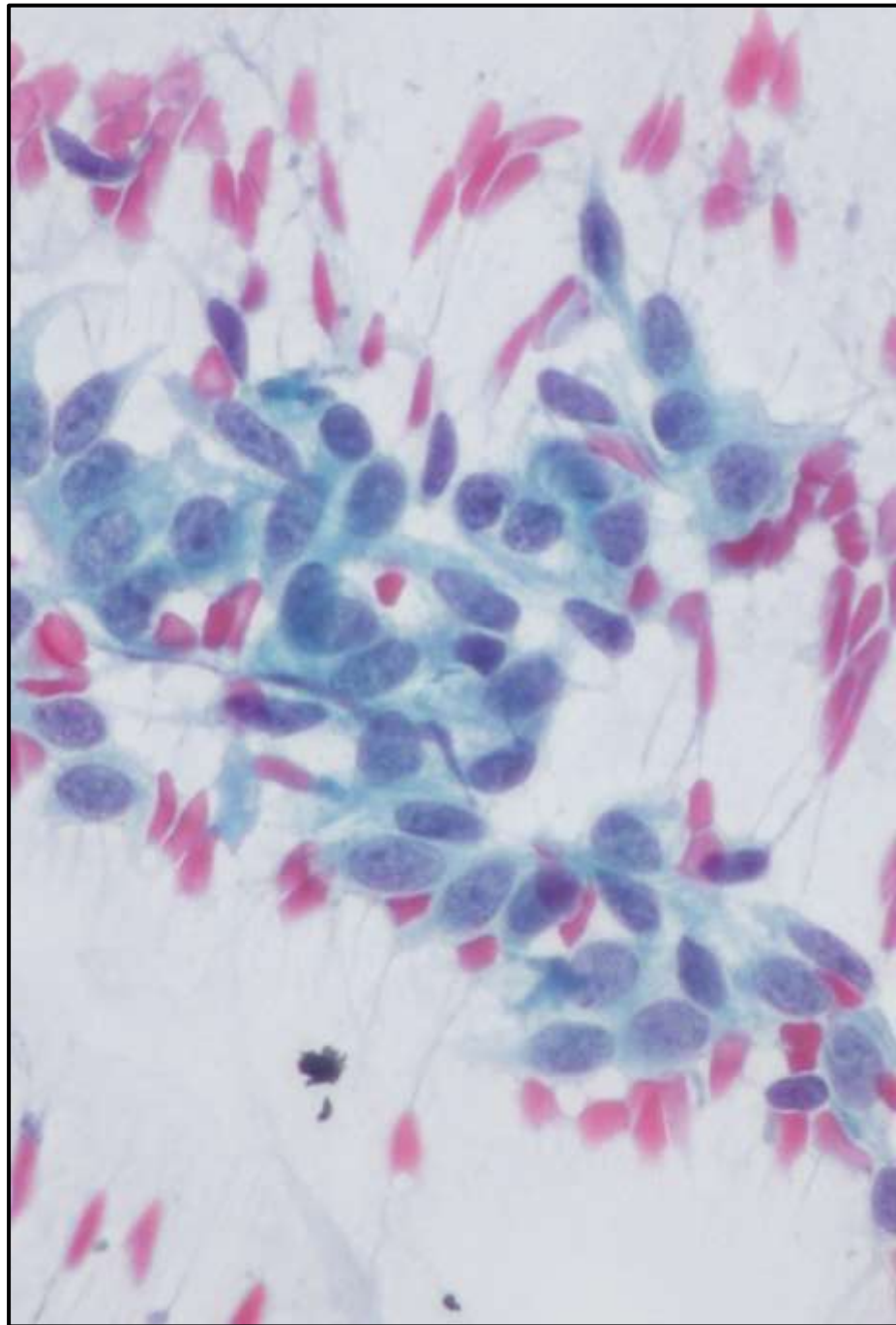
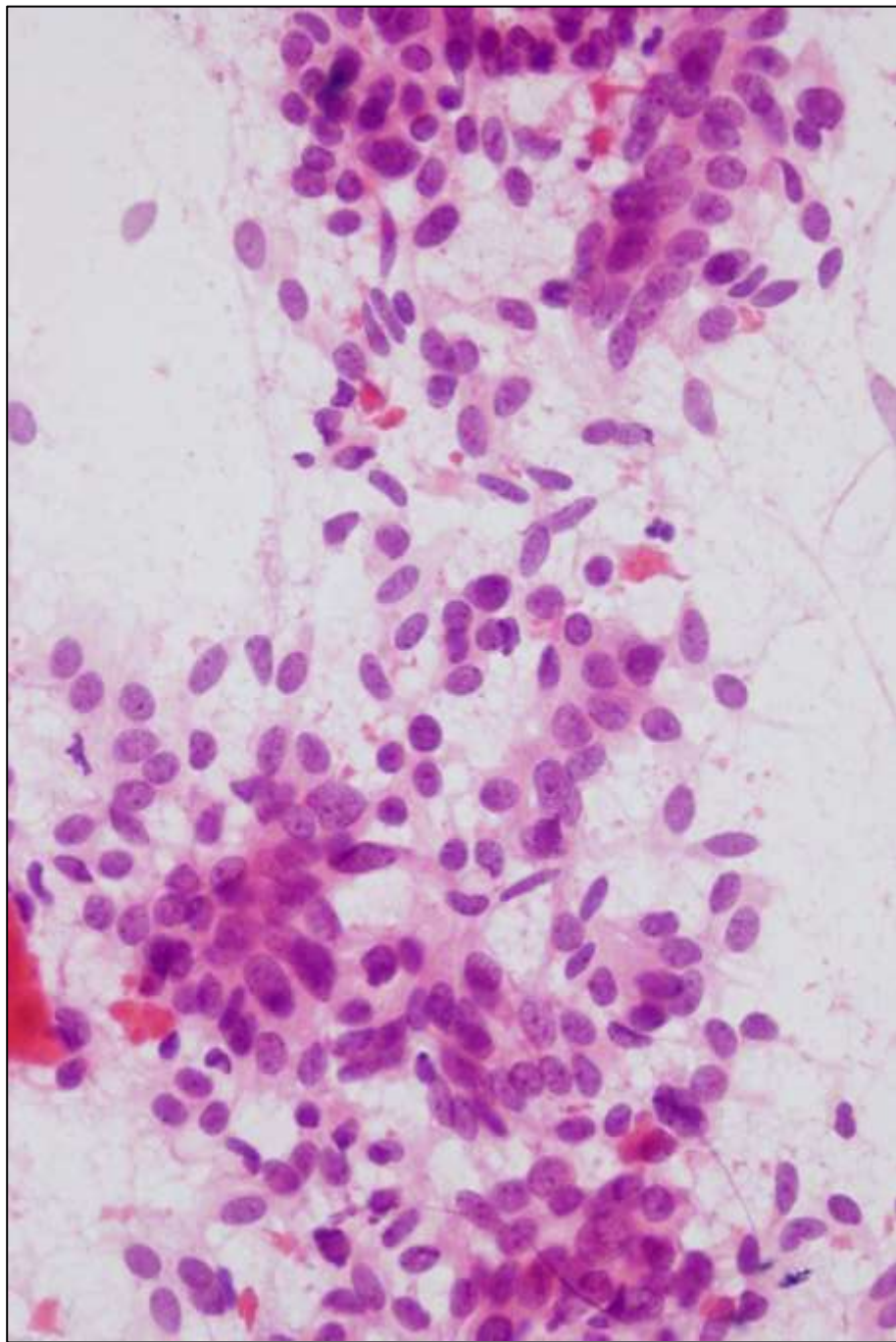


Tdt

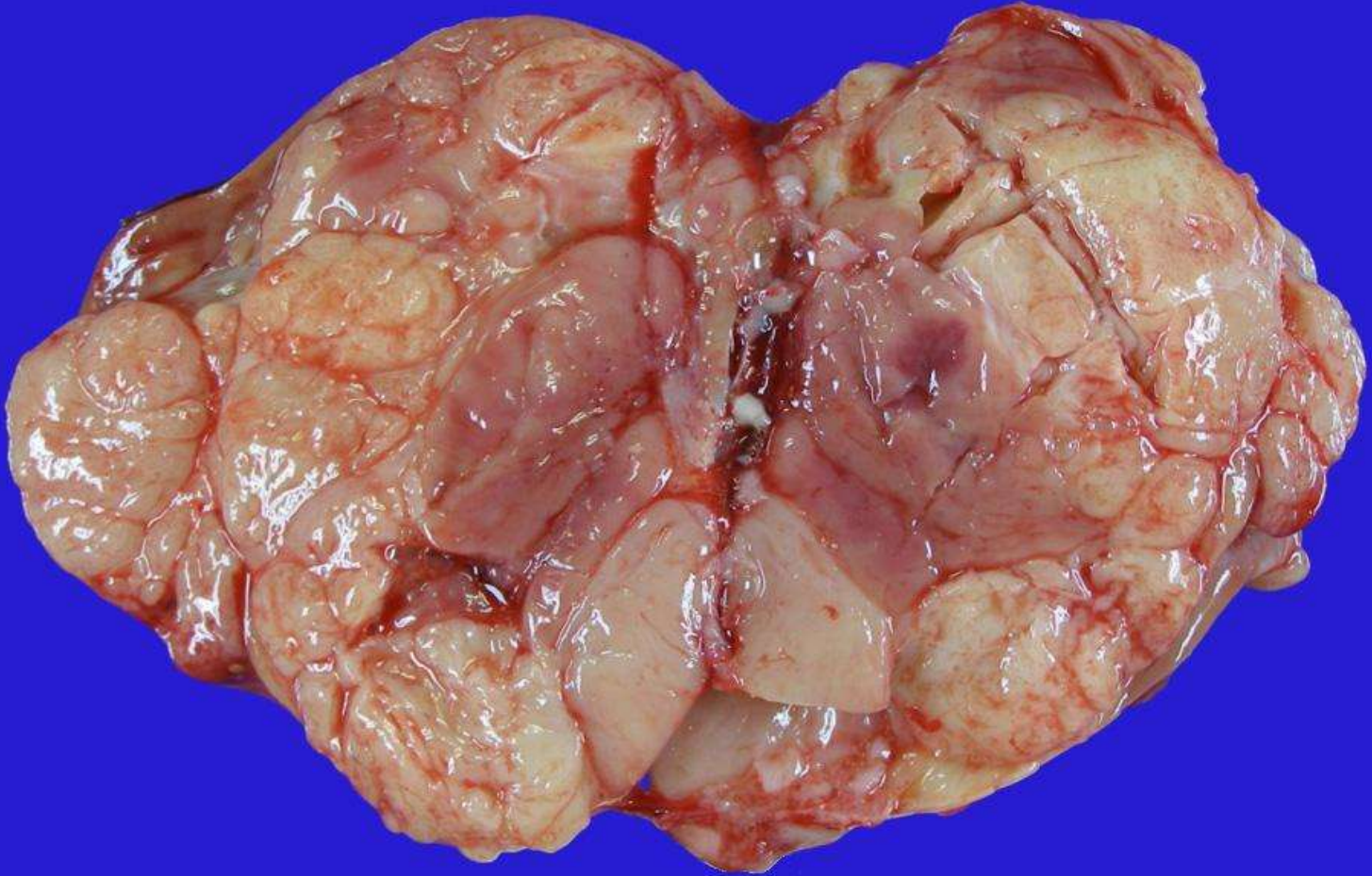
SARCOMA EWING/PNET

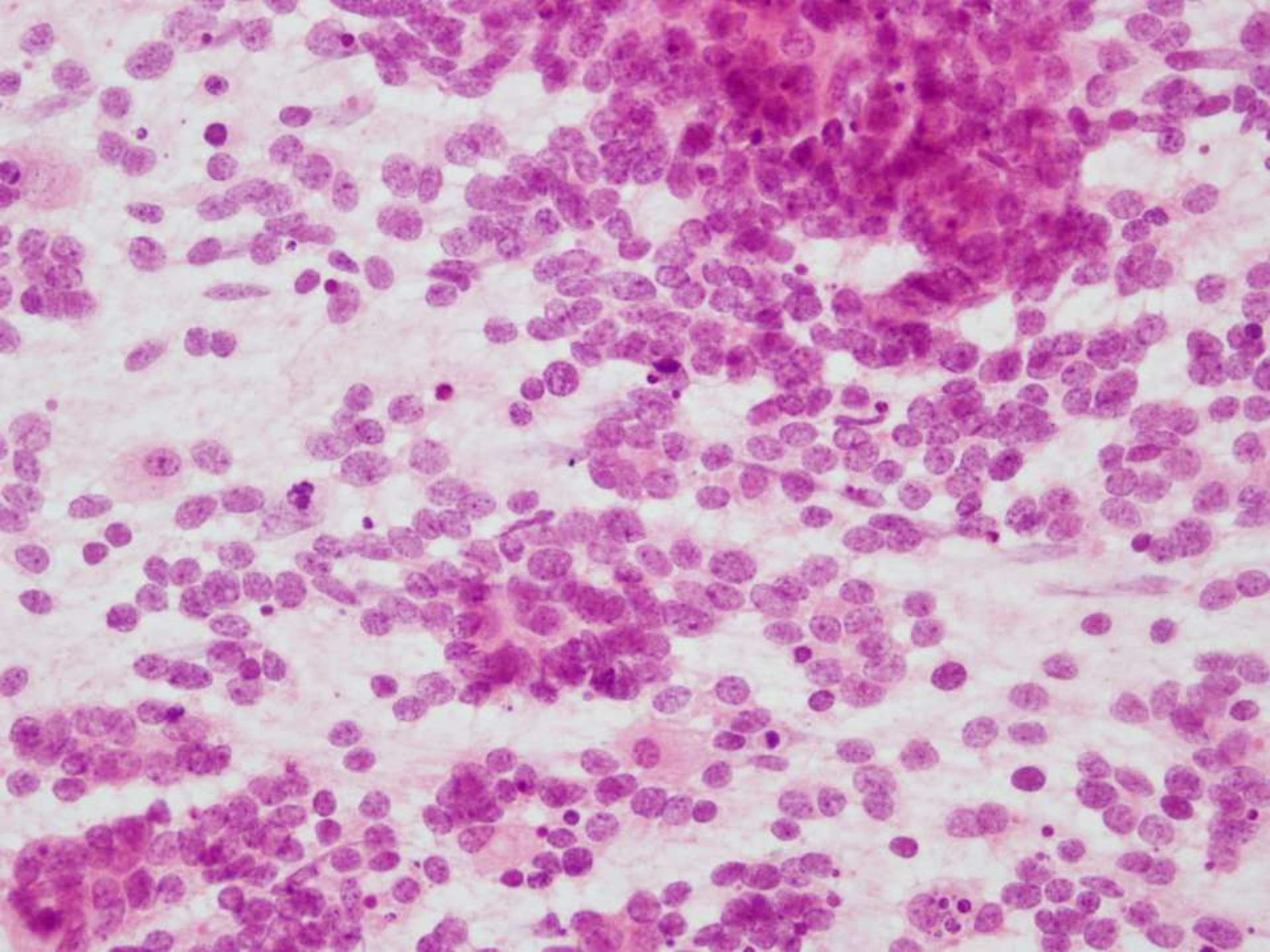


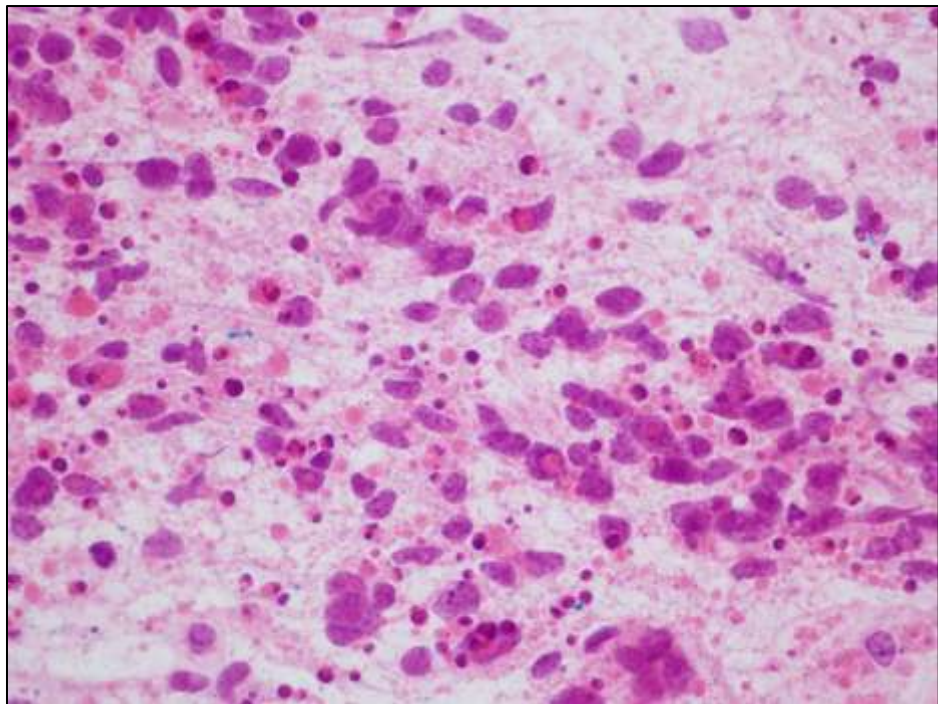
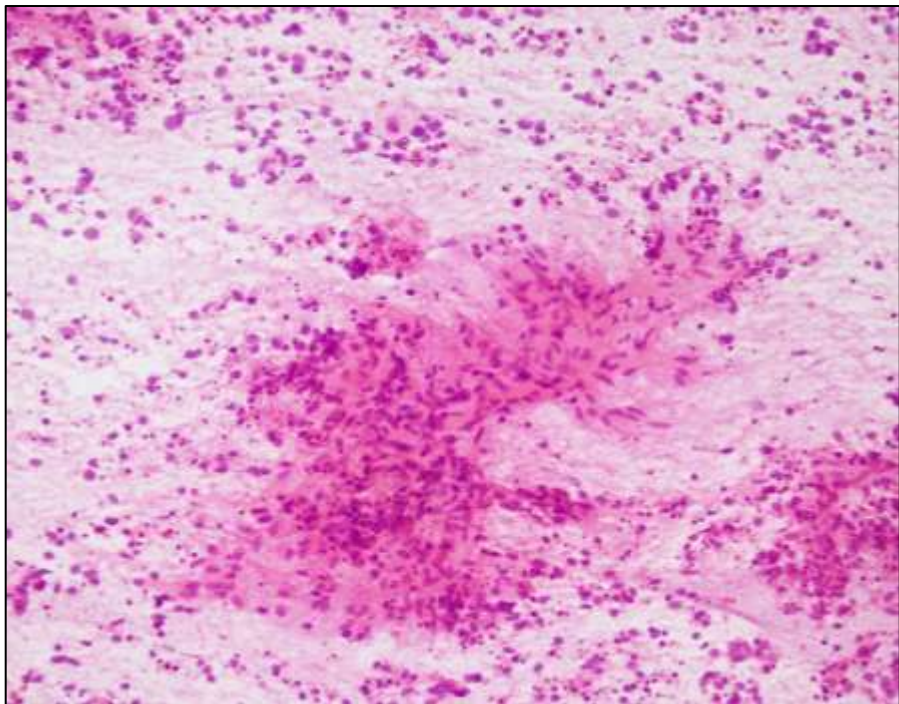
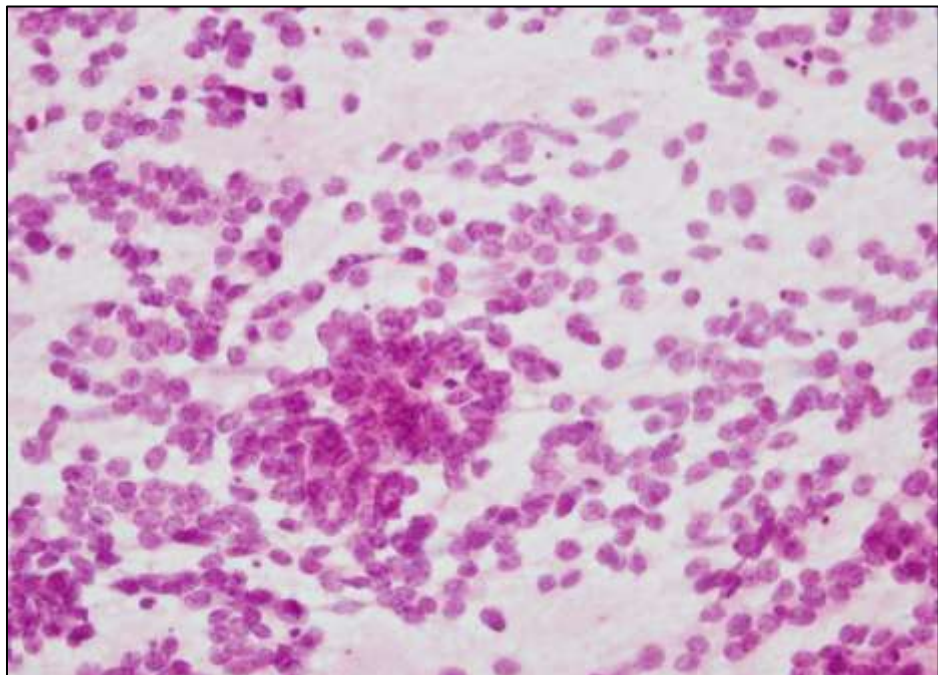
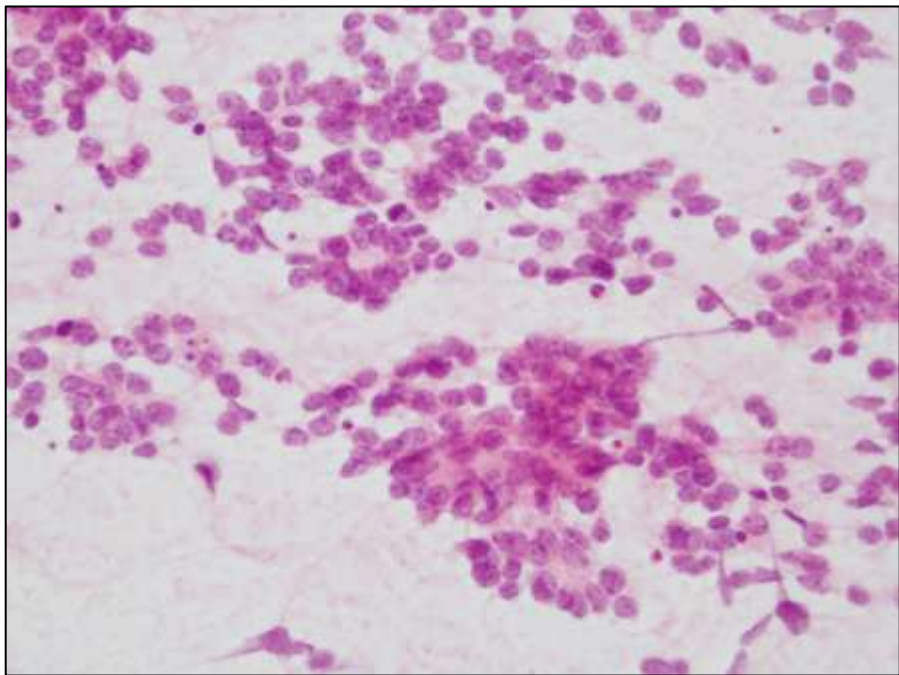
SARCOMA SINOVIAL

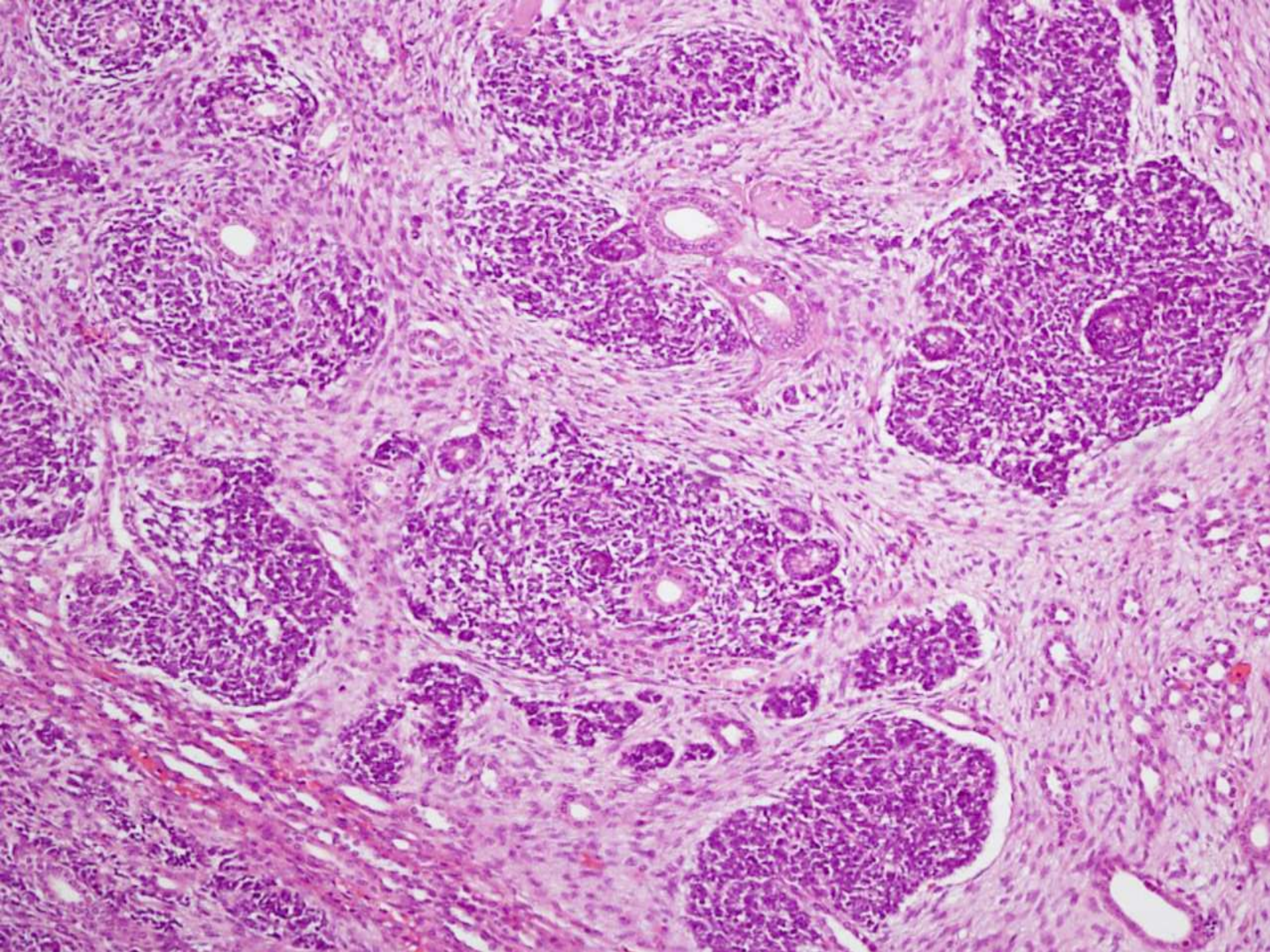


NEFROBLASTOMA









CONCLUSIONS

- Indispensable en l'estudi intraoperatori
 - Millor detall cel·lular
 - Ràpid
- Millor orientació inicial
 - Priorització d'estudis moleculars
 - Determina la viabilitat tumoral

Gràcies